

## Task Force Report

# Diagnosis and management of aortic dissection\*

## Recommendations of the Task Force on Aortic Dissection, European Society of Cardiology†

**R. Erbel (Chairman), F. Alfonso, C. Boileau, O. Dirsch, B. Eber, A. Haverich, H. Rakowski, J. Struyven, K. Radegran, U. Sechtem, J. Taylor, Ch. Zollikofer.**  
Internal reviewers: **W. W. Klein, B. Mulder and L. A. Providencia**

### Table of contents

Preamble .....	1642	Magnetic resonance imaging .....	1661
Introduction.....	1643	Aortography .....	1662
Aortic wall disease.....	1643	Intravascular ultrasound.....	1663
Inherited disease .....	1643	Surgical and interventional therapy .....	1664
Aortic disease in infancy and childhood .....	1645	Surgical therapy .....	1664
Ageing of the aorta.....	1645	Interventional therapy by percutaneous stenting and/or percutaneous fenestration.....	1668
Aetiology of aortic aneurysm and dissection .....	1647	Indications for stent placement and fenestration.....	1668
Aortic dissection staging .....	1648	Interventional techniques .....	1669
class 1 — classical aortic dissection .....	1649	Results of interventional therapy.....	1670
class 2 — intramural haemorrhage/haematoma .....	1649	Complications of interventional therapy .....	1670
class 3 — subtle/discrete aortic dissection.....	1650	Follow-up in aortic dissection.....	1670
class 4 — plaque rupture/ulceration.....	1650	Natural history of aortic dissection and prognosis .....	1670
class 5 — traumatic/iatrogenic aortic dissection .....	1651	Follow-up in Marfan patients .....	1671
Clinical management .....	1651	Imaging for follow-up studies.....	1672
Clinical features .....	1651	Reoperation .....	1672
Initial diagnostic steps in the emergency room .....	1652		
Initial therapeutic decisions .....	1653		
Diagnostic requirements.....	1654		
Evolving — acute aortic dissection .....	1654		
Additional information.....	1657		
Imaging modalities .....	1658		
Transthoracic/transoesophageal echocardiography (TTE/TEE).....	1659		
Computed tomography.....	1660		

Manuscript submitted 24 April 2001, and accepted 2 May 2001.

\*This document has been reviewed by members of the Committee for Scientific and Clinical Initiatives and by members of the Board of the European Society of Cardiology (see Appendix 2), who approved the document in the year 2001. The document received the ACC Endorsement by the Board of Trustees of the American College of Cardiology in the year 2001 (see Appendix 3). The full text of this document is available on the website of the European Society of Cardiology in the section 'Scientific Information', Guidelines and the ACC is listing the document under 'ACC Endorsement' on their website with a link to the ESC website.

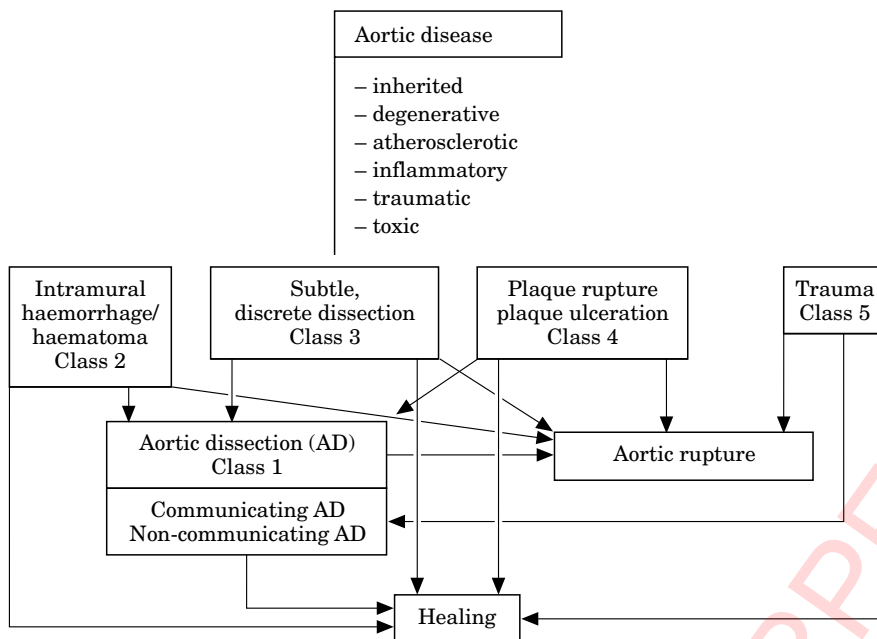
†For affiliations of Task Force Member see Appendix 1.

### Preamble

Provisional guidelines were prepared by the ESC Task Force on Aortic Dissection, as suggested by the committee for Scientific Clinical Initiatives and approved by the ESC Board at its meeting on 17 June 1997.

This Task Force consists of 11 members, including representatives of the European Association of Radiology, and the European Society of Pediatric Cardiology, as well as one member appointed by the American College of Cardiology in order to gain ACC endorsement. The members were all appointed by the Board of the ESC upon suggestions made by the committee for Scientific Clinical Initiatives. In addition, controversial issues were discussed between the members on an e-mail platform as well as via telephone conferences.

Review of the literature and position papers were prepared. At the request of the committee for Scientific Clinical Initiatives, the Task Force delineations were presented at the congress of the ESC in August 1999 by U. Sechtem in the conference on emerging guidelines.



**Figure 1** Schematic illustration of different aortic disease aetiologies which can result in aortic dissection including progression or regression of the disease.

Finally, the document was distributed for correction and endorsement to all members and intermittently reviewed for consistency by internal reviewers. An effort was made to include all relevant evidence relating to the diagnosis and treatment of aortic dissection. The members were aware of the fact, that for diagnostic tests and surgical as well as interventional procedures related to aortic dissection, no evidence-based medical data for group A and B were available, so that a grading concerning consensus between the members was chosen. Grading C<sub>I</sub> meant consensus of all members, grade C<sub>II</sub> consensus of the majority of the members, but with data not supporting this decision, grade C<sub>III</sub> no consensus, no or little data available supporting this view.

## Introduction

Cardiovascular diseases are the major cause of death in the majority of the developed countries and in many developing countries, as reported by the Task Force of the European Society of Cardiology and proven by European cardiovascular mortality and morbidity statistics<sup>[1]</sup>.

Aortic diseases contribute to the high overall cardiovascular mortality. New imaging modalities — transoesophageal echocardiography, magnetic resonance imaging, helical computed tomography, electron beam computed tomography — were introduced during the last decade. These new imaging techniques allow better and earlier diagnosis of aortic diseases even in emergency situations. These new imaging techniques have changed patient management during recent years, allowing more rapid diagnosis and decision making<sup>[2–6]</sup>.

Despite this rapid progress, overall agreement about the strategy for patient management has not yet been achieved. For this reason, this Task Force obtained opinions from a wide variety of experts with the goal of formulating recommendations for the best diagnostic strategies to be followed. The diagnostic process was to be based on clinical assessment and the use of the different imaging techniques available in order to establish a rapid and correct diagnosis while avoiding diagnostic overkill. Finally, the Task Force will comment on therapeutic strategies in patients with acute aortic syndromes.

## Aortic wall disease

All mechanisms (Fig. 1) that weaken the aortic wall, the aortic lamina media in particular, lead to higher wall stress, which can induce aortic dilatation and aneurysm formation, eventually resulting in aortic dissection or rupture.

### Inherited disease

Three major inherited disorders are found in this group: Marfan's syndrome, Ehler-Danlos syndrome and other familial forms of thoracic aortic aneurysm and dissection.

#### Marfan's syndrome

Marfan's syndrome<sup>[7,8]</sup> is an autosomal dominant connective tissue disorder with an estimated incidence of 1/5000; although more than 25% of cases are probably sporadic. The syndrome involves many systems: skeletal, ocular, cardiovascular, pulmonary, skin and integument, and dura. In 1986, an international group of

experts agreed upon diagnostic criteria to distinguish Marfan's syndrome from related disorders. This criteria set is currently referred to as the 'Berlin nosology'<sup>[7]</sup>. This nosology did not fit in many individual cases and revised criteria were recently proposed, known as the new 'Gent nosology'<sup>[8]</sup>. These new criteria include more stringent requirements for diagnosing Marfan's syndrome in relatives of an unequivocally affected individual. Particular attention is paid to skeletal involvement as a major criterion if at least four of eight typical manifestations are present, also to the potential contribution of molecular analysis to the diagnosis of Marfan's syndrome and the delineation of criteria for diagnosing other inherited conditions that overlap with Marfan's syndrome. Since collagen and elastin abnormalities are a prominent feature of this disorder, Marfan's syndrome was long considered a defect of either one of these. However, protein and gene studies demonstrated conclusively that neither one was involved. Sakai and co-workers identified a new extracellular matrix protein which they named 'fibrillin'<sup>[9]</sup>. This protein is the major constituent of microfibrils found in the extracellular matrix, as either isolated aggregates or closely associated with elastin fibres. To date more than 100 different mutations have been identified in the fibrillin-1 gene in patients with Marfan's syndrome<sup>[10]</sup>. The mutations are found in complete and incomplete forms of Marfan's syndrome but also in a spectrum of overlapping diseases, some of which are also associated with aortic dissection: the Shprintzen-Goldberg syndrome<sup>[11]</sup>, familial or isolated forms of aortic aneurysms<sup>[12]</sup> and the 'MASS' phenotype<sup>[13]</sup>. These results define the new molecular group of 'type 1 fibrillinopathies'<sup>[14]</sup>.

The clinical variability seen in Marfan's syndrome is only partly explained by the great number of mutations identified in the fibrillin-1 gene. Genetic heterogeneity and the involvement of a second gene (MFS2 for Marfan syndrome type 2)<sup>[15]</sup> was demonstrated in a French family.

The percentage of cases of Marfan's syndrome associated with mutations in MFS2 is unknown. However, through protein studies, several teams have established that between 7% and 16% of patients with Marfan's syndrome have normal fibrillin metabolism<sup>[16,17]</sup>.

#### Summary

Marfan's syndrome displays a wide clinical variability. A number of mutations have been identified, particularly for the fibrillin-1 (FBN-1) gene. Genetic criteria are helpful for identifying incomplete forms of the Marfan syndrome.

#### Ehler-Danlos syndrome

Ehler-Danlos syndrome (EDS) is a heterogeneous group of hereditary connective tissue disorders characterized by articular hypermobility, skin hyperextensibility and tissue fragility. Eleven types of EDS have been charac-

terized. There are no well-founded figures on the prevalence of EDS. An estimated incidence of 1/5000 births is often stated; this is an aggregate frequency for the disease. There is no racial or ethnic predisposition<sup>[18]</sup>. Aortic involvement is seen primarily in EDS type IV<sup>[19]</sup>, which is transmitted in an autosomal dominant fashion. However, approximately 50% of cases are new mutations<sup>[19]</sup>. In the recently revised nosology, EDS type IV is the only member of the 'EDS vascular type'<sup>[20]</sup>. The disease is caused by structural defects in the pro $\alpha$ 1(III) chain of collagen type III encoded by the COL3A1 gene located on chromosome 2q31<sup>[21,22]</sup>.

#### Summary

Aortic involvement is typical for Ehler-Danlos syndrome, a connective tissue disorder characterized by articular hypermobility, skin hyperextensibility and tissue fragility. The disease is caused by structural defects in the pro  $\alpha$ -1 (III) chain of collagen type III.

#### Annuloaortic ectasia and familial aortic dissection

The term annuloaortic ectasia was first used in 1961 by Ellis *et al.* to describe a clinical feature, now recognized as a condition affecting 5% to 10% of patients who undergo aortic valve replacement for pure aortic regurgitation<sup>[23]</sup>. Two recent studies have analysed familial aggregation of thoracic aortic dilatation and dissection. The relative risk of a patient's father, brothers and sisters developing aortic aneurysms was 1.8, 10.9 and 1.8, respectively<sup>[10]</sup>. This report also supports evidence of a sex-linked disease process. In 38.5% of the families there was evidence of autosomal dominant transmission, in 23.1% of autosomal dominant or X-linked and in 26.9% of either an autosomal or X-linked recessive mode<sup>[24]</sup>. These reports not only underscore the importance of familial aggregation but also the very probable existence of genetic heterogeneity.

Five mutations in the FBN1 gene have now been identified in patients presenting with either sporadic or familial forms of thoracic aortic aneurysms and dissection<sup>[13,25]</sup>. Other genes may also be involved. Histological examination of the aortic wall reveals loss of elastic fibres, deposits of mucopolysaccharide-like material and cystic medial anomalies, as is also found in patients with Marfan's syndrome<sup>[26]</sup>. No abnormalities of types I and III collagen or of fibrillin were found in fibroblast cultures. Furthermore, indirect immunofluorescence studies of the microfibrillar fibre array did not reveal findings typically associated with Ehlers-Danlos or Marfan's syndrome.

#### Summary

Annuloaortic ectasia is diagnosed in 5%–10% of patients undergoing aortic valve replacement for aortic regurgitation. Familial aggregation of thoracic aortic dilatation and dissection is present. No abnormal type I and III collagen or fibrillin is found.

### Abdominal aortic aneurysms and dissection

Abdominal aortic aneurysm formation or dissection is uncommon before the sixth decade. A high proportion of cases are symptomatic, and the process is very often associated with more proximal aortic involvement<sup>[27]</sup>. Many studies reported familial aggregation of abdominal aortic aneurysms<sup>[28]</sup>. The risk among people with an affected first-degree relative was estimated to be 11.6-fold. More patients are women; affected men tend to be younger than affected women. The risk of rupture seems to be strongly correlated with familial disease and 63% are female and 37% male<sup>[29]</sup>. Segregation analyses of data from 91 families revealed that the disease was very likely determined by a major autosomal diallelic locus and a recessive disease-causing allele<sup>[30]</sup>. An autosomal dominant pattern with a frequency of 1/250 for the morbid allele and an age-related penetrance no higher than 0.4 was described in 313 pedigrees<sup>[31]</sup>.

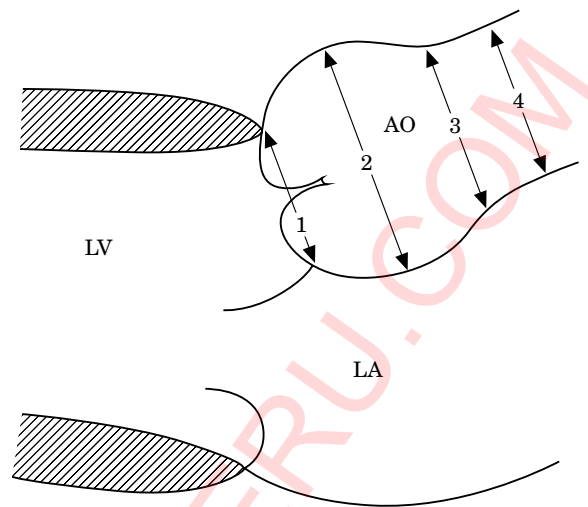
The disease is probably very heterogeneous at the genetic level. Furthermore, careful examination of the pedigrees often reveals involvement not only of the abdominal aorta but also disease in its more proximal segments, as well as other clinical features suggestive of Marfan's or Ehlers-Danlos syndrome. Today it is therefore difficult to differentiate pure familial forms of abdominal aortic aneurysm/dissection from thoracic aortic aneurysms/dissection with an abdominal component. This is underscored by the fact that the only molecular defect reported to date is that of a mutation within the COL3A1 gene<sup>[32]</sup>. In fact, many candidate genes have been investigated that encode various collagens, fibrillins, fibrullins, microfibril-associated glycoproteins, matrix metalloproteinases and their inhibitors, but no mutation has been identified.

### Aortic disease in infancy and childhood

The aortic diameter increases steadily throughout life. Standard measurement locations for the aortic root are described for children (Fig. 2). Nomograms relating aortic size to body surface area have been published (Fig. 3)<sup>[33]</sup>.

Aortic dissection is rare in infants and children younger than 16 years, and is not always associated with Marfan's syndrome or other connective tissue disorders. Only two cases occurring in the Marfan population were described during the last 10 years<sup>[33,34]</sup>. Dissection has, however, been reported in normal infants following infection<sup>[35]</sup>, and as a consequence of surgical trauma<sup>[36]</sup>. Primary balloon dilatation of aortic coarctation as well as dilatation of re-coarctation may produce damage to the aorta with subsequent development of an aneurysm. A degree of intimal tearing and dissection can always occur<sup>[37]</sup>. Dissection originating from the site of aortic cannulation, particularly if the aortic wall is thin, is a recognized complication of cardiopulmonary bypass<sup>[38]</sup>.

Even in Marfan's syndrome aortic dissection is not always associated with aneurysmal dilatation of the aortic root<sup>[39]</sup>, and dissection may originate from an area of non-dilated aorta, irrespective of the aortic root



**Figure 2** Schematic presentation of the longitudinal parasternal view with four regions where aortic diameters are measured for follow-up analysis in Marfan's syndrome. LV=left ventricle; LA=left atrium; 1=valve annulus; 2=aortic sinuses; 3=sinotubular junction; 4=proximal ascending artery. (Reprinted from *Am J Cardiol*, Volume 64, Roman MJ, Devereux RB, Kramer, Fox R, O'Loughlin J. Two-dimensional echocardiographic aortic dimensions in children and adults, pp. 507–512 with permission from Excerpta Medica Inc.)

dimensions. This was reported in a large series of cardiac operations in children with Marfan's syndrome<sup>[40]</sup>. A close association seems to be present between bicuspid aortic valves and aortic dilatation resulting in aortic regurgitation, aneurysm formation and aortic dissection.

Dissection has been reported in association with coarctation of the aorta, both above and below the coarctation site. This complication is not seen in childhood, but as a complication of untreated coarctation — usually in the third decade or later and in association with hypertension. Dissection involving the descending aorta below the coarctation site is reported as a complication of pregnancy<sup>[41]</sup>. Dissection also occurs in young adults, but not in children with a bicuspid aortic valve and ascending aortic dilatation<sup>[42]</sup>.

Although homocystinuria is associated with a phenotype similar to Marfan's syndrome, the vascular lesions tend to be of thrombotic or occlusive nature<sup>[43]</sup>. There are no reports of abdominal aortic dissection in childhood, but abdominal aortic aneurysms are recorded<sup>[44]</sup>.

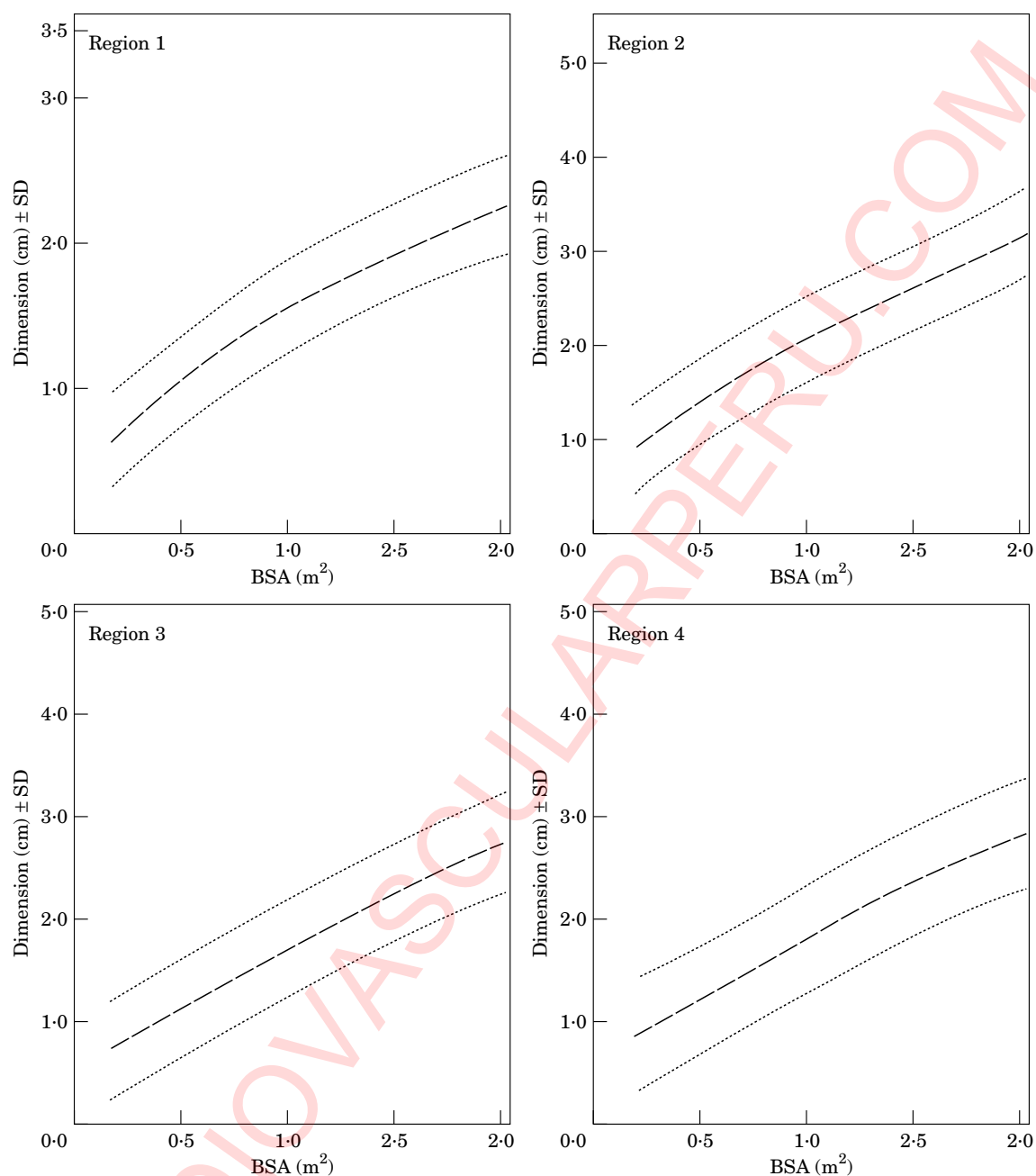
#### Summary

Standard measurements and nomograms are helpful for assessing aortic root size related to body surface area. Aortic dissection is rare in infants and children. Dissection has been reported with dilatation of aortic coarctation and recoarctation.

### Ageing of the aorta

Normal aortic values have been reported for adults (Table 1). The expansion rate over 10 years is about





**Figure 3** Aortic diameter changes related to body surface area (BSA) for the four different regions illustrated in Fig. 2. Useful for follow-up studies and detection of abnormal enlargement of the aorta in Marfan's syndrome. (Reprinted from *Am J Cardiol*, Volume 64, Roman MJ, Devereux RB, Kramer, Fox R, O'Loughlin J. Two-dimensional echocardiographic aortic dimensions in children and adults, pp. 507–512 with permission from Excerpta Medica Inc.)

1.2 mm<sup>[49,50]</sup>. Factors that weaken the aortic wall can lead to aneurysm formation. According to the law of La Place ( $\sigma = p \times r/2h$ ), wall stress ( $\sigma$ ) in a thin wall model is directly proportional to pressure ( $p$ ) and radius ( $r$ ) and inversely proportional to vessel wall thickness ( $h$ ). This makes hypertension as well as cystic media necrosis factors related to the development of aortic disease<sup>[51–53]</sup>. The expansion rate of aneurysm in the ascending aorta is about  $1.3 \pm 1.2 \text{ mm} \cdot \text{year}^{-1}$  and in the abdominal

aneurysm  $3.1 \pm 3.2 \text{ mm} \cdot \text{year}^{-1}$ <sup>[54]</sup>. Interestingly, aortic diameters in cases with and without dissection were found to be the identical (6 cm vs 6.4 cm)<sup>[55]</sup>. The same holds true for Marfan's syndrome: this means that ascending aortic diameters are 7.4 cm (5.6–10.0 cm) in dissection cases and 6.9 cm (5.3–9.0 cm) in cases without dissection<sup>[39,56,57]</sup>. A ratio of the diameter of the aneurysm to the normal aorta of less than 2.2 indicates a lower risk for rupture of the abdominal aorta<sup>[58]</sup>. The

**Table 1 Normal aortic dimensions in adults**

Diameter		
Aortic annulus		
Male	2.6 ± 0.3 cm	TTE <sup>[33]</sup>
Female	2.3 ± 0.2 cm	TTE <sup>[33]</sup>
Sinus of Valsalva		
Male	3.4 ± 0.3 cm	TTE <sup>[33]</sup>
Female	3.0 ± 0.3 cm	TTE <sup>[33]</sup>
Aortic root	<3.7 cm	TTE <sup>[33]</sup>
Proximal ascending aorta		
Male	2.9 ± 0.3 cm	TTE <sup>[33]</sup>
Female	2.6 ± 0.3 cm	TTE <sup>[33]</sup>
Ascending aorta	1.4–2.1 cm . m <sup>-2</sup> <3.8 cm (2.5–3.8) <3.7 cm	TEE <sup>[45]</sup> CT <sup>[2]</sup> TTE <sup>[46]</sup>
Descending aorta	1.0–1.6 cm . m <sup>-2</sup> <2.8 cm (1.7–2.8)	TEE <sup>[45]</sup> CT <sup>[2]</sup>
Wall thickness		
Aortic wall	<4 mm <3 mm <4 mm	CT <sup>[47]</sup> Angio <sup>[48]</sup> TEE <sup>[49]</sup>

ratio was 2.7 in symptomatic patients and 3.4 in a group with evidence of rupture<sup>[59]</sup>. Thus, the risk of aortic aneurysmal rupture seems to be related to the aortic diameter (Table 2). An increase in the aortic diameter of pre-existing aneurysms is lower in the thoracic than in the abdominal aorta<sup>[52]</sup>, a fact possibly related to the vasa vasorum being absent in the abdominal aorta<sup>[64]</sup>. If aortic dissection is present, an expansion rate of 5–20 mm within 3 years can be expected. The rate is 1 mm . year<sup>-1</sup> for non-communicating and 2–3 mm . year<sup>-1</sup> for communicating dissection<sup>[65]</sup>.

### Aetiology of aortic aneurysm and dissection

Atherosclerosis is the main cause of aortic aneurysms<sup>[66,67]</sup>. Atherosclerosis leads to gross thickening of the intima. The intima shows massive fibrosis and calcification, and increased amounts of extracellular fatty acids. The integrity of this layer can be compromised by the extracellular matrix being degraded by histiocytic cells. Additional degenerative changes can develop within the fibrous tissue. These changes are characterized by reduced cellularity and collagen fibre hyalinization. Both mechanisms may lead to intimal rupture, most often at the edges of plaques.

Intimal thickening increases the distance between the endothelial layer and the media, compromising the nutrient and oxygen supply. Adventitial fibrosis may obstruct vessels feeding small intramural vasa vasorum. Reduced nutritional supply of the media results in medial thinning secondary to necrosis — primarily due to necrosis of the smooth muscle cells. Another consequence is a fibrotic change in the elastic structures of the medial layer<sup>[64]</sup>. All these changes contribute to increased vessel stiffness and to higher vulnerability to shear stress, eventually leading to the formation of aneurysms and dissections, especially in the infrarenal aorta<sup>[66]</sup>.

In cases of aortic aneurysms severe aortic atherosclerosis involves more than 70% of the surface in over 90% of the patients<sup>[68]</sup>. Ruptures are more common in the ascending aorta (65%) and less frequent in the abdominal aorta (32%). Fusiform thoracic aortic aneurysms have a higher rupture risk (61%) compared to abdominal aortic aneurysms<sup>[67]</sup>. Aortic rupture is found in 0.9% of cases of sudden death. Aortic dissections are present in 62% of these patients, atherosclerotic aneurysms in 37% and false aneurysms in 1.6%<sup>[67]</sup>.

The main risk factor for aneurysm formation in atherosclerosis is hypertension, which is found in 85% of those with ruptured or 52% of those with non-ruptured aneurysms<sup>[67]</sup>. The risk factors, e.g. smoking and hypercholesterolaemia, are also associated with an increased incidence of aortic aneurysms<sup>[68]</sup>. However, 60% of patients have a cholesterol level of less than 240 mg . dl<sup>-1</sup> (6.2 mmol . l<sup>-1</sup>)<sup>[68]</sup>.

Secondary to high-speed accidents, 15%–20% of deaths are related to aortic trauma. About 95% of the injuries occur at the site of greatest stress, the aortic isthmus, only 5% at the ascending aorta<sup>[69]</sup>. Aortic disruption can be limited to the intima or include the entire wall. Chronic aneurysms tend to become symptomatic or rupture within 5 years. Aortic rupture will ultimately occur in most patients mainly after forming pseudoaneurysms, which can enlarge and compress surrounding structures like the pulmonary artery<sup>[70]</sup>. Aortic rupture after blunt chest trauma is frequently associated with myocardial contusion which can lead to cardiac failure, myocardial infarction, and tamponade.

Aneurysm formation and aortic rupture can also occur after aortic surgery and even after cardiopulmonary resuscitation<sup>[71–73]</sup>. Extracorporeal shock

**Table 2 Aortic diameters in aneurysms with or without dissection: indications for surgery in different patient groups**

Authors	Results	Patient population and method
Lemon <sup>[60]</sup>	No difference in diameter	With and without dissection (angiography)
McDonald <i>et al.</i> <sup>[61]</sup>	>5.5 cm	Marfan's syndrome — surgery
Roberts <sup>[51]</sup>	>5.3 cm	Marfan's syndrome — dissection
White <i>et al.</i> <sup>[62]</sup>	>6.0 cm	Computed tomography (CT)
Tijon-A-Meeuw <sup>[63]</sup>	0.2–0.4 cm/year >5 cm surgery, as 30% rupture in <2 years	Aortic diameter increase
Sütsch <sup>[55]</sup>	Surgery before 6 cm is reached	Transoesophageal echocardiography

**Table 3** Types of vasculitis predominately involving large and medium-sized vessels<sup>[78]</sup>

- 
- (1) Takayasu's aorto-arteritis
  - (2) Giant cell arteritis
    - (a) Temporal arteritis
    - (b) Disseminated giant cell arteritis
    - (c) Primary angitis of the central nervous system (considered by many as a viral infection)
  - (3) Behcet's disease
  - (4) Aortitis associated with rheumatoid disease
  - (5) Inflammatory abdominal aortic aneurysm (aetiology unknown — probably an immune response to lipids infiltrating the aortic wall)
  - (6) Aortitis in relation with retroperitoneal fibrosis (Ormond's disease)
- 

waves can produce aortic injury as well<sup>[74]</sup>. Another possible cause of trauma is cardiac catheterization as a diagnostic or interventional procedure<sup>[75]</sup>. Aortic dissection may be observed in patients who underwent prior aortic valve replacement. The interval between valve replacement and dissection varies greatly<sup>[76,77]</sup>. The mechanism which revealed an area of condensed resistance within the aortic wall may have been the jet lesion which produced the post stenotic ascending aortic dilatation similar to aortic wall disease in aortic stenosis and regurgitation. However, distal aortic dissection has also been observed after aortic valve replacement, suggesting additional risk factors for this occurrence<sup>[76,77]</sup>.

Inflammatory diseases can destroy the medial layers of the aortic wall and lead to weakening of the aortic wall, hastening expansion and causing higher wall stress. Suppurative bacterial or fungal aortitis is rare. It can cause focal destruction of the vessel wall with subsequent aneurysm formation and/or rupture. Autoimmune diseases of the aorta (Table 3) can severely affect the vasa vasorum, and decrease the blood supply of the media<sup>[78]</sup>. Furthermore, inflammatory lesions — as seen in Takayasu arteritis — may develop inside the aortic wall. Such inflammatory lesions consist of an inflammatory infiltrate, smooth muscle and fibroblast necrosis, and fibrosis of the vessel wall (for a review see:<sup>[79]</sup>). Inflammation related to infectious diseases, such as luetic aortitis, can lead to similar changes. Aortitis is the principal cardiovascular manifestation of syphilis, found mainly in the ascending aorta, but distal segments can be involved<sup>[80]</sup>.

Rheumatoid arthritis can also lead to aortitis. Secondary typical aortic dissections are unusual. The diseased aorta may rupture. Toxic aortic disease is seen in animals after the administration of beta-aminopropionitrile fumarate which leads to changes in the media morphologically similar to mucoid degeneration of the aortic wall<sup>[81]</sup>. Other chemicals have been shown to cause cellular necrosis in the media (for a review see:<sup>[82]</sup>). The administration of high doses of zinc can also lead to aortic dissections in animal models<sup>[83]</sup>. In humans, different drugs such as cocaine and amphetamine are associated with aneurysm formation and aortic dissection<sup>[84,85]</sup>.

#### Summary

Hypertension is a main risk factor of aortic sclerosis and subsequent aortic aneurysm formation and aortic dissection.

Smoking and hypercholesterolaemia are additional risk factors.

15%–20% of death secondary to high speed accidents are related to aortic trauma, frequently associated with myocardial contusion.

Iatrogenic aortic dissection is often related to cardiac catheterization, angioplasty, or surgery.

Inflammatory diseases can affect the aorta as in Takayasu arteritis and syphilis as well as in Behcet's or Ormond's disease.

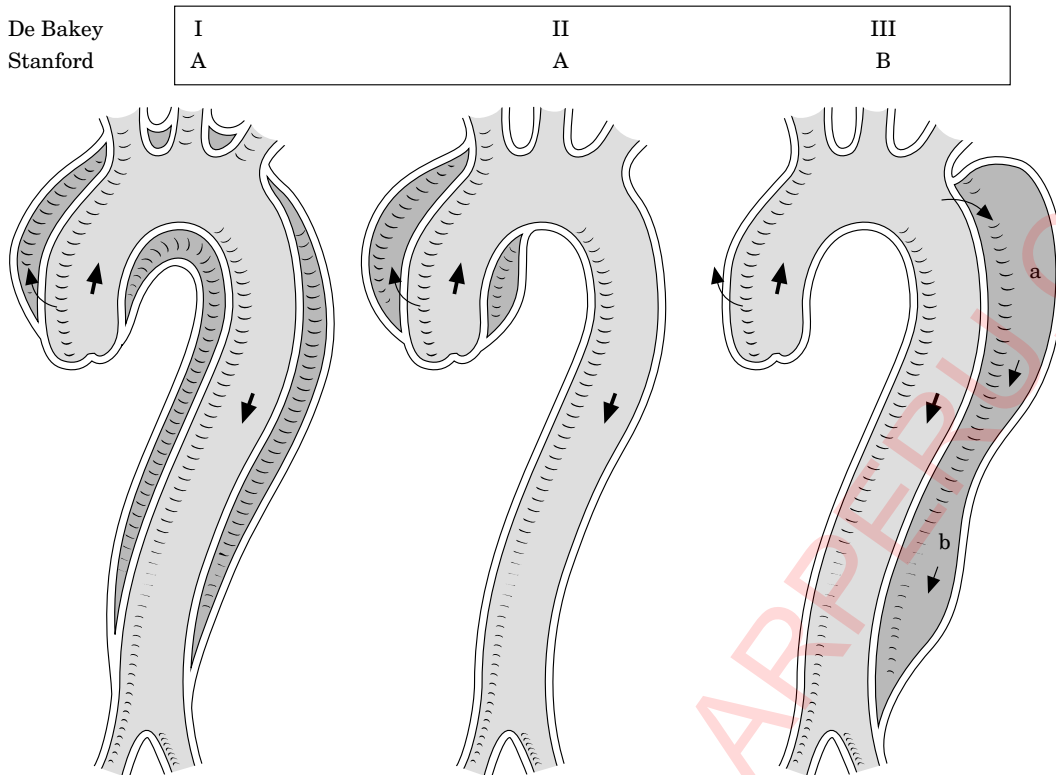
Cocaine and amphetamine associated with aortic aneurysm formation and dissection are newly detected aetiologies.

### Aortic dissection staging

The Stanford classification of aortic dissection distinguishes between type A and type B (Fig. 4)<sup>[86,87]</sup>. Type A means the dissection includes the ascending aorta, a type B dissection does not involve the ascending aorta. The De Baakey classification subdivides the dissection process further: a type I dissection involves the entire aorta, a type II dissection involves the ascending aorta, and a type III dissection the descending aorta<sup>[87]</sup>. The first attempt to further subdivide the De Baakey classification was made by Reul and Cooley (Fig. 4), differentiating from thoracic abdominal type III dissection<sup>[88]</sup>. Subdividing into proximal and distal or ascending and descending aortic dissections is also common.

New studies demonstrated that intramural haemorrhage, intramural haematoma and aortic ulcers may be signs of evolving dissections or dissection subtypes. Consequently, a new differentiation (Fig. 5) has been proposed<sup>[89]</sup>.

- class 1: classical aortic dissection with an intimal flap between true and false lumen
- class 2: medial disruption with formation of intramural haematoma/haemorrhage



**Figure 4** Schematic drawing of aortic dissection class 1, subdivided into DeBakey types I, II and III. Also depicted are Stanford classes A and B with subtypes a and b (subtype depends on the thoracic or abdominal involvement according to Reul and Cooley<sup>[88]</sup>).

class 3: discrete/subtle dissection without haematoma, eccentric bulge at tear site

class 4: plaque rupture leading to aortic ulceration, penetrating aortic atherosclerotic ulcer with surrounding haematoma, usually subadventitial

class 5: iatrogenic and traumatic dissection

All classes of dissection can be seen in their acute and chronic stages; chronic dissections are considered to be present if >14 days have elapsed since the acute event or if they are found occasionally.

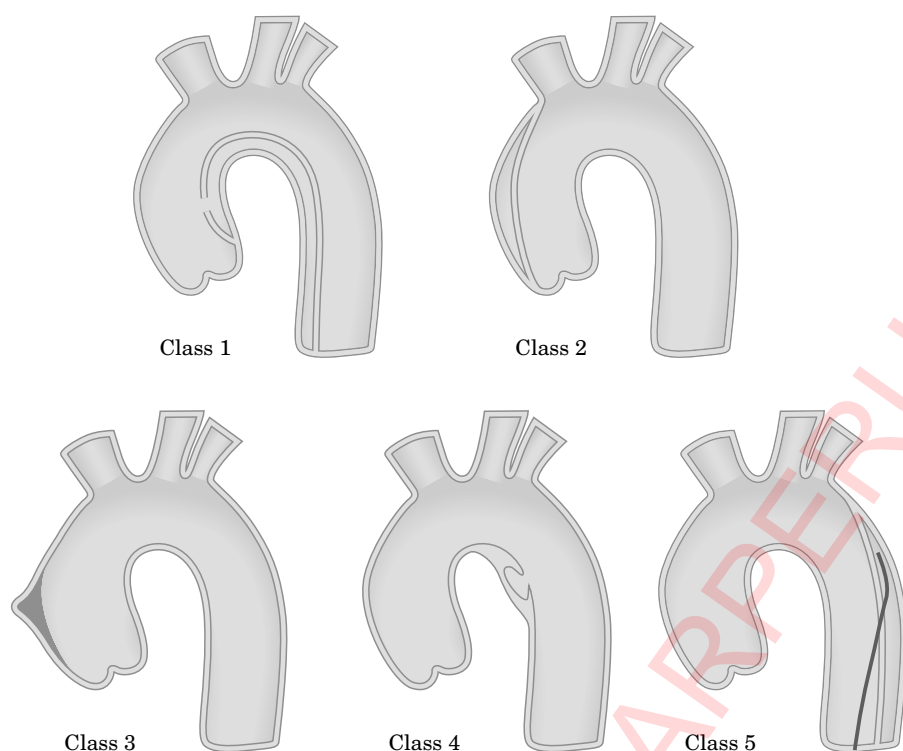
### *Classic aortic dissection (class 1)*

Acute aortic dissection is characterized by the rapid development of an intimal flap separating the true and false lumen<sup>[51]</sup>. Due to the pressure difference the true lumen is usually smaller than the false lumen. Intimal flap tears characterize communicating dissections<sup>[6]</sup>. However, tears are not always found and non-communicating dissections are not uncommon<sup>[6,91–99]</sup>. In an autopsy study, dissecting aneurysms without tears were found in up to 12% of 311 autopsies<sup>[95]</sup>. Others have reported an incidence of 4% in 505 cases<sup>[97]</sup>. In a series of sudden deaths, 67% of patients with dissections did not have tears<sup>[99]</sup>. The dissection can spread from diseased segments of the aortic wall in an antegrade or retrograde fashion, involving side branches and causing other complications<sup>[6,93,94]</sup>.

### *Intramural haematoma/haemorrhage (class 2)*

An intramural haematoma is probably the initial lesion in the majority of cases of cystic medial degeneration. This leads to aortic dissection in which the intimal tear seems to be secondary to preceding intramural dissection<sup>[95–104]</sup>. Intramural haematoma/haemorrhage may be the result of ruptured normal-appearing vasa vasorum which are not supported by the surrounding aortic media or the result of rupture of diseased vasa vasorum<sup>[64,96]</sup>. As a dissection the haematoma can extend along the aorta. The weakened inner wall is subjected to the elongating force of the diastolic recoil, which can result in intimal tears only visible at surgery or autopsy. Differences in elasticity between the aortic fibrous adventitia and the inner more elastic media may play an additional role<sup>[97]</sup>. From class 2 aortic dissection, the class 1 non-communicating classical dissection, which shows all signs of dissection, — an intimal flap, a true and false lumen but no flow within the false lumen due to the absence of an intimal tear, — has to be separated. The class 2 dissection may have an intramural haematoma, but also can present as diffuse — haemorrhagic — intramural bleeding, giving the impression of wall thickening. If intramural haematoma is present, only a discrete and very localized separation of wall layers occurs, which may be very superficial or deeply located within the aortic wall: multiple layerings may be observed.





**Figure 5** Differentiation of classes 1–5 of aortic dissection. Class 1: classic aortic dissection with true and false lumen without communication of the two lumina; class 2: intramural haemorrhage or haematoma; class 3: ulceration of aortic plaque following plaque rupture; class 4: subtle or discrete aortic dissection with bulging of the aortic wall; class 5: iatrogenic or traumatic aortic dissection, illustrated by a catheter induced separation of the intima. (From Svensson LG, Labib SB, Eisenhauser AC, Butterfly JR. Intimal tear without haematoma. *Circulation* 99: 1331–6, 1999; American Heart Association; reproduced with permission.)

The prevalence of intramural haemorrhage and haematoma in patients with suspected aortic dissection, as observed by various new imaging techniques, seems to be in the range of 10–30%<sup>[90,92,101,104]</sup>.

There are two distinct types of intramural haematoma and haemorrhage:

Type I shows a smooth inner aortic lumen, the diameter is usually less than 3.5 cm, and the wall thickness greater than 0.5 cm. Echo-free spaces (seen echocardiographically) as a sign of intramural haematoma are found in only one third of the patients. The mean longitudinal extent of the haematoma is 11 cm and the echo free spaces show no signs of flow<sup>[91]</sup>.

Type II occurs in aortic atherosclerosis. A rough inner aortic surface with severe aortic sclerosis is characteristic; the aorta is dilated to more than 3.5 cm and calcium deposits are frequently found. Mean wall thickness is 1.3 cm with a range of 0.6–4 cm, and echo free spaces are found in 70% of the patients studied. The longitudinal extension has a range similar to type I haematoma, usually about 11 cm<sup>[91]</sup>. Intramural haemorrhages are found more often in the descending than in the ascending aorta<sup>[91]</sup>.

The fact that intramural haemorrhage and haematoma can lead to aortic dissection has been demonstrated in follow-up studies<sup>[90–92,101,104]</sup>. Acute aortic

dissection as a consequence of intramural haemorrhage and haematoma develops in 28–47% of the patients<sup>[90–92,101,104]</sup>. It is associated with aortic rupture in 21–47%; and regression is seen in about 10% of patients<sup>[90–92,101,104]</sup>.

#### *Subtle-discrete aortic dissection (class 3)*

The structural weakness can lead either to clinically inapparent disease or minor forms of aortic dissection. Subtle dissection has been described<sup>[89]</sup> as a partial stellate or linear tear of the vessel wall, covered by thrombus. When the partial tear forms a scar, this constellation is called an abortive, discrete dissection. Partial ruptures of the inner layer of the aorta allow blood to enter the already damaged media and thus cause dissection of the aortic wall, eventually leading to a second lumen within the wall, to a rupture or healing during follow-up<sup>[89]</sup>.

#### *Plaque rupture/ulceration (class 4)*

Ulceration of atherosclerotic aortic plaques can lead to aortic dissection or aortic perforation<sup>[105–110]</sup>. This was

first observed by computed tomography<sup>[105,106]</sup>. The new imaging techniques — intravascular ultrasound, spiral computed tomography and magnetic resonance imaging — provide new insights. The ability to diagnose aortic ulceration has thereby been improved and further insight into the pathophysiology of this condition has been gained<sup>[107]</sup>. The ulcers seem to affect the descending thoracic aorta, as well as the abdominal aorta, and are not usually associated with extensive longitudinal propagation or branch vessel compromise<sup>[103]</sup>. Valvular, pericardial or other vascular complications appear rare. The ulcer may penetrate beyond the intimal border, often with a nipple-like projection with subjacent type II intramural haematoma formation<sup>[91,108]</sup>. The continuous erosion of the atherosclerotic plaque may eventually violate the internal elastic membrane<sup>[106]</sup>. False aneurysms, aortic rupture or dissections may occur<sup>[109,110]</sup>.

### *Traumatic/iatrogenic aortic dissection (class 5)*

Blunt chest trauma usually causes dissection of the ascending aorta and/or the region of the ligamentum Botalli at the aortic isthmus. Iatrogenic dissection of the aorta rarely occurs during heart catheterization. It is regularly seen following angioplasty of an aortic coarctation (in adults), but can also be observed after cross-clamping of the aorta and after intra-aortic balloon pumping<sup>[71,75,111,112]</sup>. Most catheter-induced dissections are retrograde dissections. They will usually decrease in size as the false lumen thromboses<sup>[112]</sup>. Proximal progression of the coronary dissection into the aortic root may be observed<sup>[112]</sup>.

#### *Summary*

##### **Stanford classification**

Type A — dissection of the ascending and descending aorta

Type B — dissection of the descending aorta

##### **De Baake classification**

Type 1 — dissection of the entire aorta

Type 2 — dissection of the ascending aorta

Type 3 — dissection of the descending aorta

##### **New classification**

class 1: classical aortic dissection with an intimal flap between true and false lumen

class 2: medial disruption with formation of intramural haematoma/haemorrhage

class 3: discrete/subtle dissection without haematoma, eccentric bulge at tear site

class 4: plaque rupture leading to aortic ulceration, penetrating aortic atherosclerotic ulcer with surrounding haematoma, usually subadventitial

class 5: iatrogenic and traumatic dissection

Class 1–5 represent a subdivision to the Stanford or De Baake classification

**Table 4 Aortic dissection — common presenting symptoms**

Pain
Pain alone
Pain with syncope
Pain with signs of congestive heart failure
Pain with cerebrovascular accident (stroke)
Congestive heart failure without pain
Cerebrovascular accident without pain
Abnormal chest roentgenogram without pain
Pulse loss without pain

**Table 5 Aortic dissection — differential diagnosis**

Acute coronary syndrome with and without ST-elevation
Aortic regurgitation without dissection
Aortic aneurysms without dissection
Musculoskeletal pain
Pericarditis
Mediastinal tumours
Pleuritis
Pulmonary embolism
Cholecystitis
Atherosclerotic or cholesterol embolism

## Clinical management

### *Clinical features*

#### *Symptoms*

The main challenge in managing acute aortic dissection is to suspect and thus diagnose the disease as early as possible.

The typical patient with aortic dissection presenting to an emergency department today is a male in his 60s with a history of hypertension who suffers with abrupt onset of chest pain<sup>[113–115]</sup>. The following clinical manifestations (Table 4) of acute aortic dissection are present in up to 90% of patients presenting in the emergency room:

- Pain of abrupt onset with its maximum at the time of onset (Table 4). With further extension of the dissection process, the pain may change its location accordingly. The pain is described as sharp more often than tearing, ripping, or stabbing<sup>[113–115]</sup>. In contrast, the pain associated with acute myocardial infarction starts slowly and gains in intensity with time. It is usually more oppressive and dull.
- In proximal dissections, the pain is usually located retrosternally, whereas distal dissections are characterized by interscapular as well as back pain.
- Hypertension is typically associated with distal aortic dissection.

Differential diagnoses need to be taken into account (Table 5). One also needs to be aware of less common presentations. Chest pain may be absent, but this is usually indicative of chronic aortic dissection. Up to 20% of patients with acute aortic dissection may present with syncope without a history of typical pain or

neurological findings<sup>[113–115]</sup>. Following a period of pain, cardiac failure may become the main symptom and is usually related to severe aortic regurgitation. Cardiac tamponade may result in hypotension and syncope. Syncope may also result from severe pain, obstruction of cerebral vessels or activation of aortic baroreceptors. Cerebrovascular manifestations and limb ischaemia with pulse deficits are caused by obliteration of the peripheral vessel by involvement of the vessel origin into the dissection or obliteration of the true lumen by an expanding false lumen. Paraplegia may suddenly develop as intercostal arteries are separated from the aortic lumen by the dissection. Involvement of the renal arteries may result in oliguria or anuria. Further propagation of the dissection at a later point in time will usually result in another (2nd) attack of the same acute pain as at the initial event, and is often associated with a deteriorating clinical picture<sup>[115]</sup>. When the dissection results from some form of trauma, albeit iatrogenic, it is the circumstance rather than symptoms that should alert one to that possibility. High fever is not common but can occur due to the release of pyrogenic substances from the aortic wall. It can persist for a longer period of time and may be misinterpreted as a sign of another inflammatory disease<sup>[73,116]</sup>.

Persistent abdominal pain, elevation of acute phase proteins, and increase of lactate dehydrogenase are indicators of involvement of the coeliac artery. This is observed in about 8% and involvement of the mesenteric artery in 8–13%<sup>[116,117]</sup>.

#### *Physical examination*

Physical examination can provide important clues as to the presence and origin of the aortic dissection. Whereas pulse deficits were found in 50% of patients with proximal aortic dissection in their 70s<sup>[114]</sup>, a large current registry of patients with acute aortic dissection reported this finding in less than 20% of patients<sup>[115]</sup>. These pulse phenomena may be transient due to the intimal flap's changing position. Neurological deficits (loss of consciousness, ischaemic paresis) occur in up to 40% of patients with proximal aortic dissection<sup>[114,117]</sup>. On rare occasions, symptoms such as vocal chord paralysis (caused by compression of the left recurrent laryngeal nerve), haemoptysis or haematemesis (due to haemorrhage into the tracheobronchial tree or perforation into the oesophagus)<sup>[118]</sup>, superior vena cava syndrome<sup>[119]</sup>, upper airway obstruction due to compression, Horner's syndrome (due to compression of the superior cervical sympathetic ganglion), signs suggestive of pulmonary embolism (if there is extravasation of blood from the false channel into the common adventitia of the ascending aorta and pulmonary artery leads to severe compression of the pulmonary artery<sup>[120]</sup>) or signs of mesenteric or renal ischaemia may be encountered<sup>[115,121,122]</sup>. If the iliac bifurcation is completely obstructed, Leriche's syndrome with pulse loss in both legs will occur, which is typically painless.

A diastolic murmur indicative of aortic regurgitation is present in about half of the patients with

proximal aortic dissection<sup>[113,115,122]</sup>. Occasionally, the murmur can be very faint and the typical wide pulse pressure as well as other peripheral signs of severe aortic regurgitation may be absent. Signs of pericardial involvement such as the presence of a pericardial friction rub, jugular venous distension or a paradoxical pulse should alert the physician to call for rapid surgical intervention.

Pleural effusions may be caused by rupture of the aorta into the pleural space, the left side is usually involved. Pleurocentesis reveals the presence of blood indicating the need for emergency surgery. However, an effusion may simply be the expression of an exudative inflammatory reaction from the dissected aorta and no further action is required.

Up to 30% of patients later found to have aortic dissection are initially suspected to have other conditions, such as acute coronary syndromes, non-dissecting aneurysms, pulmonary embolism, or aortic stenosis<sup>[112,114,122]</sup>. Consequently, the differential diagnosis of acute aortic dissection should always be considered in patients presenting with unexplained syncope, stroke, acute onset of congestive heart failure, and acute ischaemia of extremities or viscera, even when the typical chest pain of aortic dissection is not the leading symptom (Table 6). In these patients, an imaging procedure needs to be carried out as soon as possible to rule out or to confirm the presence of dissection.

#### *Initial diagnostic steps in the emergency room*

Although speed is of utmost importance, an ECG (Table 6) must be acquired in all patients. This test helps distinguish acute myocardial infarction, for which thrombolytic therapy may be life saving, from aortic dissection, in which thrombolytic therapy may be detrimental<sup>[123]</sup>. Both conditions may coexist as the dissecting membrane may extend into a coronary ostium (usually that of the right coronary artery) causing acute myocardial ischaemia. Such coronary involvement will induce in the ECG signs of acute myocardial infarction and this in turn could result in potentially detrimental administration of thrombolytic therapy. However, a normal ECG is present in one third of patients with coronary involvement and most of these patients have non-specific ST-T segment changes<sup>[123]</sup>. About 20% of patients with type A dissection have ECG evidence of acute ischaemia or acute myocardial infarction<sup>[123]</sup>. These patients with suspected aortic disease and ECG evidence of ischaemia must undergo diagnostic imaging before thrombolytic therapy is administered. The chest X-ray is not sufficient to rule out aortic dissection<sup>[124]</sup>. However, diagnostic imaging cannot be performed in all patients presenting with myocardial ischaemia, and erroneous administration of thrombolytic therapy may be unavoidable in the occasional patient who is subsequently found to have aortic dissection, but an enlarged mediastinum may indicate an unsuspected aortic dissection.

**Table 6 Initial management of patients with suspected aortic dissection**

Recommendation	Class	Level of evidence
1. Detailed medical history and complete physical examination (whenever possible)	•	C
2. Intravenous line, blood sample (CK, TnT(I), myoglobin, WBC, D-dimer, haematocrit, LDH)	•	C
3. ECG: documentation of ischaemia	•	C
4. HR and blood pressure monitoring	•	C
5. Pain relief (morphine sulphate)	•	C
6. Reduction of systolic blood pressure using beta-blockers (i.v. propranolol, metoprolol, esmolol or labetalol)	•	C
7. Transfer to intensive care unit	•	C
8. In patients with severe hypertension additional vasodilator (i.v. sodium nitroprusside to titrate BP to 100–120 mmHg)	•	C
9. In patients with obstructive pulmonary disease, blood pressure lowering with calcium channel blockers	•	C
10. Imaging in patients with ECG signs of ischaemia before thrombolysis if aortic pathology is suspected	•	C
11. Chest X-ray	•	C

The role of the chest X-ray is currently unclear (Table 6)<sup>[124]</sup>. A routine chest X-ray will be abnormal in between 60%<sup>[115]</sup> to 90% of cases<sup>[113]</sup> with suspected aortic dissection and will thus make the diagnosis of aortic dissection more likely. However, in unstable patients, a chest X-ray will result in further delay before instituting treatment and should thus be omitted.

The often large wound surface and haematoma may be reflected in laboratory findings such as elevated C-reactive protein, mild-to-moderate leukocytosis and slight elevations of bilirubin and lactic acid dehydrogenase<sup>[125]</sup>. More recently, the biochemical diagnosis of aortic dissection has become possible by identifying raised concentrations of smooth muscle myosin heavy chain<sup>[125]</sup>.

### Initial therapeutic decisions

Every patient with suspected aortic dissection should undergo diagnostic imaging by one of the techniques discussed below to rule out the disease. The benefits of this strategy outweigh the risks of being harmful to patients ultimately found to have another condition<sup>[126]</sup>. Whilst arranging for appropriate testing, the patient needs to be moved to an intensive care unit for appropriate monitoring (Table 6). As fluid replacement may become of utmost importance in cases of haemodynamic deterioration, drugs should be infused through a separate intravenous line. In the unstable patient, invasive blood pressure monitoring should be provided by placing an arterial line to the right radial artery. If involvement of the brachiocephalic trunk is suspected (rarely seen), this line should be placed on the left side. It is important to rule out the presence of pseudo-hypotension due to obstruction of an aortic arch branch. Therefore pressure measurement on both arms is important.

While waiting for diagnostic imaging, it is necessary to control pain and reduce systolic blood pressure to values between 100 and 120 mmHg (Table 6). The most

appropriate drug to provide pain relief is morphine sulphate. Beta-blockers as a group of drugs have the most desirable effect of reducing the force of left ventricular ejection (dp/dt) which continues to weaken the arterial wall. Intravenous beta-blockers such as propranolol (0.05–0.15 mg per kg of body weight every 4 to 6 h<sup>[127]</sup>) or esmolol (administered at a loading dose of 0.5 mg . kg<sup>-1</sup> over 2–5 min followed by an infusion of 0.10–0.20 mg . kg<sup>-1</sup> min<sup>-1</sup>) can be given. It needs to be remembered that the maximum concentration of esmolol is only 10 mg . ml<sup>-1</sup>. The infusion of this agent at a maximal dose of 0.3 mg . kg<sup>-1</sup> min<sup>-1</sup> constitutes a substantial volume load. Metoprolol and atenolol are also available for intravenous application, but have a longer half-time. Labetolol, a drug which blocks both alpha- and beta-adrenergic receptors, can also be used in patients with aortic dissection. In patients with potential intolerance to beta-blockers (those with bronchial asthma, bradycardia, signs of heart failure) esmolol (with its short half life) seems to be a reasonable choice to test the patient's reaction to beta-blockers. There are no data supporting the use of calcium antagonists in these patients, but drugs such as verapamil, diltiazem, or nifedipine may be necessary in order to reduce blood pressure, particularly in patients with bronchial asthma.

If beta-blockade alone does not control hypertension, vasodilators are ideal additional agents to control blood pressure. However, as vasodilators can increase the force of left ventricular ejection, they should always be combined with beta-blockers (Table 6). While beta-blocking agents are usually adequate in patients with slightly elevated blood pressure, combination with intravenous sodium nitroprusside may be required for more severe hypertension. The initial dose is 0.25 µg . kg<sup>-1</sup> min<sup>-1</sup>. Systolic blood pressure should be titrated to values between 100 and 120 mmHg. Lowering of systolic blood pressure must be modified if oliguria or neurological symptoms develop.

In patients with normal or even reduced systolic blood pressure at presentation, possible volume depletion —



**Table 7 Management of haemodynamically unstable patients with suspected aortic dissection**

Recommendation	Class I	II	III	Level of evidence
1. Profound haemodynamic instability: intubation and ventilation	•			C
2. Transoesophageal echocardiography as the sole diagnostic procedure — call surgeon		•		C
3. Surgery-based on findings of cardiac tamponade by transthoracic echocardiography		•		C
4. Pericardiocentesis (lowers intrapericardial pressure (recurrent bleeding!))			•	C

which may be the result of blood sequestration in the false lumen or the pleural and pericardial space — has to be ruled out. Patients with profound haemodynamic instability (Table 7) need to be intubated and ventilated without delay. Transoesophageal echocardiography can be performed as the sole diagnostic procedure in the intensive care unit or later in the operating theatre<sup>[3,128]</sup>. If speed is vital, transthoracic echocardiography should be carried out immediately, but the resulting image quality is rarely adequate for decision making. The echocardiographic finding of cardiac tamponade may lead to sternotomy and exploratory surgery without further imaging. Pericardiocentesis (Table 7) as an initial therapeutic step before surgery may be harmful as this reduces intrapericardial pressure and may therefore cause recurrent bleeding<sup>[129]</sup>.

#### Summary

Aortic dissection has a wide range of clinical presentations. Clinical suspicion is required for quick risk stratification and management.

Monitoring of heart rate and blood pressure is indicated. Beta-blocking therapy and blood pressure lowering medications are started, as well as sedation and analgesic therapy.

Monitoring in the intensive care unit should be initiated. Fluid replacement may be important.

Use a separate line for blood pressure lowering. Start with beta-blocking agents and add sodium nitroprussid, if necessary.

In case of haemodynamic instability, the patient should be intubated and transferred to the operating theatre. TEE may be performed prior to transfer or in the operating theatre.

## Diagnostic requirements (Table 8)

### *Evolving — acute aortic dissection*

#### *Essential information: confirming the diagnosis*

The demonstration of an intimal flap separating two lumina is the basis for diagnosing aortic dissection class. If the false lumen is completely thrombosed, central displacement of the intimal flap, calcification or separation of intimal layers (Table 9) can be regarded as definitive signs of aortic dissection<sup>[3]</sup>.

**Table 8 Imaging: diagnostic goals**

- Confirm diagnosis
- Classify the dissection/delineate the extent
- Differentiate true and false lumen
- Localize intimal tears
- Distinguish between communicating and non-communicating dissection
- Assess side branch involvement (including coronary arteries)
- Detect and grade aortic regurgitation
- Detect extravasation (periaortic or mediastinal haematoma, pleural or pericardial effusion)

The following methods can confirm the diagnosis with high accuracy. In the large international registry of aortic dissection (IRAD), the first diagnostic step was transthoracic echocardiography (TTE) and transoesophageal echocardiography (TEE) in 33%, computed tomography (CT) in 61%, magnetic resonance imaging (MRI) in 2% and angiography in 4%<sup>[130]</sup>. In 56% TTE/TEE, in 18% CT, in 9% MRI and in 17% angiography were used as secondary techniques. Therefore an average of 1.8 methods were utilized to diagnose aortic dissection. CT was used in 40%, MR in 30% and angiography in 21% of those cases where three methods were chosen<sup>[130]</sup>.

The decision for a specific technique depends on two major factors:

- Availability in emergency situations
- Experience of the emergency room and imaging staff

Patients with acute aortic dissections are usually admitted to the emergency wards of regional hospitals, where not all methods described in the previous section are available. If aortic dissection is suspected, patients should be transferred to a centre with interventional and surgical back up. Each institution should establish their guidelines for the most rapid and accurate diagnostic steps to confirm the diagnosis. The use of two or even three imaging techniques to diagnose aortic dissection is excessive and often can lead to unnecessary time loss. As far as decision making is concerned, only experienced, well trained physicians are able to reduce the number of false diagnoses, which are more likely when the dissection is not the classical class 1 dissection, but a dissection of class 2–4<sup>[131–135]</sup>. Data relating the sensitivity and specificity of the different techniques for various scenarios are quite limited<sup>[136–138]</sup>. In class 3 dissection, only aortography — and not TEE, CT, or MRI — may make the physician aware of the presence of a discrete and subtle aortic dissection<sup>[89]</sup>.

**Table 9 Differentiate between atherosclerotic aortic aneurysm and aortic dissection**

	Atherosclerotic aortic aneurysm	Aortic dissection
Aortic diameter	↑↑	↑
Wall thickness	↑ (↑)	normal, except for: intramural haematoma; intramural haemorrhage
Luminal surface	rough	smooth
Thrombus formation	lumen	false lumen
Floating thrombi	++	false lumen
Displacement of intimal calcifications	(+)	++
Signs of slow flow	often inside the lumen	false lumen

**Table 10 Differentiation between communicating and non-communicating aortic dissection**

Communicating dissection (c)	Non-communicating dissection (nc)
<ul style="list-style-type: none"> <li>● Intimal tear</li> <li>● Flow within false lumen</li> <li>● Phasic motion of the intimal flap</li> <li>● High flow signals in the false lumen</li> <li>● No or incomplete thrombus formation in the false lumen</li> </ul>	<ul style="list-style-type: none"> <li>● Intima intact</li> <li>● No flow in false lumen</li> <li>● No/or reduced motion of the intimal flap</li> <li>● Signs of reduced flow, spontaneous echocardiographic contrast</li> <li>● Thrombus formation in the false lumen — incomplete or complete</li> </ul>

**Table 11 Aortic dissection: differentiation between true and false lumen**

	True lumen	False lumen
Size	true < false	most often false > true
Pulsation	systolic expansion	systolic compression
Flow direction	systolic antegrade flow	systolic antegrade flow reduced or absent or retrograde flow
Localization within the aortic arch	inner contour	outer contour
Signs of slow flow	rare	frequent; depending on degree of communication
Thrombus	rare	frequent; depending on degree of communication

#### *Tear localization and disease extent*

Any therapeutic intervention aims to occlude the entry tear (e.g. by stent implantation or grafting), which makes tear detection and localization very important. It is common to see not just one entry and one reentry, but multiple tears<sup>[94]</sup>. The pressure difference between the true and false lumen forces the blood from the true to the false lumen and back, but multidirectional flow jets can be observed<sup>[94]</sup>. Intimal tears can be visualized directly by TTE, TEE, CT and MRI, but also by angiography<sup>[136]</sup>. Pulsed Doppler and continuous wave Doppler can give an estimate of the pressure difference between the false and true lumen.

The full extent of aortic dissection can be analysed by ultrasonic techniques alone, if echocardiography is combined with duplex sonography, abdominal sonography — or even better — intravascular ultrasound. Due to its low image quality, duplex abdominal sonography cannot be used for unequivocal decision making. Of all ultrasonic techniques, intravascular ultrasound has gained the highest accuracy<sup>[100,101,121]</sup>, eliminating the blind spot in the ascending aorta or in

the abdomen which used to limit examinations in the past. The full extent of the dissection can be visualized non-invasively by CT, MRI or invasively by angiography.

#### *Classification of aortic dissection*

The extent (beginning and end point) of a dissection can be described by taking wall thickness and the intimal flap into account. Depending on flow in the false lumen or tears in the intimal flap, communicating and non-communicating aortic dissections (Tables 10, 11) can be distinguished. Communication is present when forward, reversed or delayed flow is detected in the false lumen. In acute communicating dissections, the intimal flap may display strong excursions during the cardiac cycle. Such movement as well as flow are reduced or absent when no communication is present. Depending on the degree of communication, thrombus formation may be observed<sup>[6,94]</sup>. Spontaneous contrast is an echocardiographic indicator (Table 10, 11) of reduced or absent flow in the false lumen<sup>[6,94]</sup>. Similar signs of reduced flow can be detected by MRI<sup>[136–138]</sup>.

Non-communicating aortic dissections should be differentiated from intramural haematomas. Intramural haematomas (class 2 aortic dissection) are more localized and restricted to one or two aortic segments; they are frequently characterized by multiple wall layers with shearing of the different components during pulsation. A class 2 dissection can progress to a class 1 dissection. Non-communicating aortic dissection in a wider sense is a class 1 dissection but without an entry tear and flow into the false lumen and should be differentiated, because these lesions have a better prognosis than class 2 dissections.

If communication is present, the entry points need to be located and described with reference to the entire dissected segment of the aorta. Antegrade dissection is present when the tear is proximal to the distal end of the dissection. When the tear is located distally to the proximal end of the dissection, retrograde progression is present. The new imaging techniques allow differentiation of these different types of dissection with high accuracy. Retrograde dissection with involvement of the ascending aorta and presence of a tear at the aortic isthmus is found in up to 20% of type A (type I) patients<sup>[6]</sup>. That means, a retrograde dissection type B (type III) can extend to the ascending aorta and evolve to a type I or type A dissection.

When class 1 or 2 dissections (Fig. 5) are excluded and typical symptoms are present, other forms of dissection, such as class 3 and 4 should be considered. Plaque ulceration following plaque rupture is typically visualized by TEE, CT or MRI<sup>[105–110,135,139–141]</sup>. It has to be taken into account that multiple lesions are often present. Each one has to be carefully checked for signs of penetration or rupture<sup>[139]</sup>.

While the patient's history may already point toward the presence of class 5 dissection, class 4 dissection may be best visualized by aortography, where it can be seen as an eccentric, discrete wall bulging<sup>[141]</sup>. Class 5 dissection resulting from iatrogenic injury will usually be evident when a false transit of the catheter is demonstrated on the aortic contrast injection. Class 5 traumatic aortic dissections are best visualized by immediate TEE in the emergency room. Nowadays newer emergency rooms may be equipped with mobile CT scanners in order to facilitate the use of CT without having to transport the patient.

#### *Indicators of emergency*

Clinically aortic dissection will often present as a two-step process. After a first event which is associated with severe pain and pulse loss, the bleeding stops. The second event sets in when the pressure exceeds a critical limit and rupture occurs, either into the pericardium with cardiac tamponade or into the pleural space or mediastinum.

Fluid extravasation into the pericardium, pleural space and/or mediastinum are indicators of urgency. These findings are frequently described in cases of sudden death in aortic dissection<sup>[6,142]</sup>. Separation of

epi- and pericardium are indicative of pericardial effusion. An effusion as little as 30 ml can be detected by echocardiography, but CT and MRI are sensitive methods as well. Fluid around the aorta is a sign of ongoing penetration or perforation, not uncommonly combined with intramural haemorrhage<sup>[6]</sup>. Fluid within the pleural space can be detected by echocardiography, CT and MRI. It is usually left sided.

Mediastinal haematomas increase the distance between aorta and oesophagus as well as left atrium. A distance of more than 1 cm is a clear indicator of mediastinal haematoma, which might even compress the left atrium. This can be detected by TEE, CT and MRI. Fluid around the aorta may be a sign of ongoing penetration, eventually resulting in rupture. It is important to identify these signs of emergency as they are associated with a mortality of greater than 50%<sup>[6]</sup>. Some deaths may even occur during additional diagnostic procedures which delay surgical intervention<sup>[6]</sup>.

#### *Assessing flow in the false and true lumen*

It is important to differentiate between true and false lumen (Table 11). The true lumen is usually compressed by the false lumen, and demonstrates systolic expansion and systolic forward flow. It is close to the inner curvature of the aortic arch. Spontaneous echocardiographic contrast as a sign of slow flow and thrombus formation is rare. The false lumen exhibits systolic compression. It is located next to the outer portion of the aorta and signs of slow flow are regularly described; at least in some part of the false lumen, if not in its entirety. Thrombus may be present<sup>[3,6,94]</sup>.

The true lumen expands during systole and collapses during diastole because the pressure changes. The collapse can be complete, giving rise to ischaemia of tissues/organs supplied by side branches. Flow and pulsation can be attenuated in the true lumen when there is no abdominal reentry.

If the false lumen is completely thrombosed it can be helpful to analyse the aortic structure in different scan fields, and to look for central displacement of calcification<sup>[2,3,90,121,137]</sup>. Further differentiation can be accomplished with colour flow and pulsed Doppler<sup>[6,94]</sup>. Flow in the false lumen is delayed, absent or even reversed<sup>[94]</sup>. In addition, communicating dissection intimal flaps show stronger pulsation than non-communicating dissection. The extent of flow visualization in the false lumen depends on the degree of communication. In patients with no or reduced communication between the true and false lumen, imaging shows absent or only reduced flow in the false lumen. If by TEE no flow is present, communication can be ruled out. Retrograde dissection can still be present, with communication occurring at a site much more distal, because no flow reaches the imaged part of the aorta<sup>[94]</sup>.

#### *Severity and aetiology of aortic regurgitation*

An elevated pressure amplitude as well as a diastolic murmur are often the presenting clinical signs of aortic

dissection. Increased left ventricular contraction with or without dilatation can be regarded as an indirect sign of aortic insufficiency. Colour flow Doppler has a high sensitivity and specificity for detecting aortic regurgitation. In addition, aortic regurgitation can be recognized and graded by cine MRI but not by CT. Aortic regurgitation can be graded angiographically. The aetiology of the regurgitation and the diameter of the aortic ring are important to the surgeon, as a decision for aortic valve replacement or resuspension has to be made. TEE is currently the best technique to assess the morphology and function of the valve and surrounding structures<sup>[77]</sup>.

#### *Signs of myocardial ischaemia*

When chest pain is present, it will not be possible to differentiate between myocardial ischaemia and/or aortic dissection. The ECG will show ST segment elevation and typical signs of acute transmural myocardial infarction when an ostium of the coronary arteries is blocked. These ECG signs may be so typical that thrombolytic therapy is started<sup>[123]</sup>. Signs of previous myocardial infarction have to be taken into account in order to be aware of coronary artery disease. Wall motion abnormalities detected by echocardiography or MRI are indicative of reduced myocardial perfusion. Another sign of ischaemia may be ST-segment depression indicating non-transmural infarction or coronary insufficiency secondary to deteriorating haemodynamics in coronary artery disease, flaps blocking the coronary ostium or collapse of the true lumen during diastole<sup>[143]</sup>.

Transoesophageal echocardiography can visualize the ostium of both arteries and image the first 2–3 cm of the left and 1–2 cm of the right coronary artery. Multislice CT and MRI may visualize the proximal coronary arteries in emergency situations even better.

Currently only coronary angiography can reliably determine whether additional coronary artery disease is present in patients with aortic dissection. In stable patients, particularly those with aortic type B (type III) dissection, coronary angiography can be performed safely and represents a part of the staging in the chronic phase of the disease<sup>[144,145]</sup>.

#### *Summary*

Essential information in involving acute aortic dissection.

- Confirmation of diagnosis
- Tear localization
- Extent of aortic dissection
- Classification of aortic dissection
- Indicators of emergency

Additional information not immediately necessary

- Arch vessel and side branch involvement
- No laboratory tests except for routine parameter assessment

### *Additional information*

#### *Supra aortic — arch involvement*

To plan acute operative interventions, knowledge of the involvement of aortic side branches is not essential as the ascending aorta will be replaced with or without valve replacement, irrespective of the extension of the dissection into side branches<sup>[87]</sup>.

Side branches of the aortic arch — the carotid arteries in particular — are best depicted angiographically, but can also be shown on duplex sonography, helical-CT and MRI. Using TEE, the innominate artery can be visualized in 70% and the left carotid artery in 30% of cases. Intravascular ultrasound with a 10 MHz transducer reliably visualizes all aortic side branches<sup>[100,121]</sup>.

#### *Involvement of abdominal aortic side branches*

Multiorgan failure is a major cause of death after medical or surgical therapy<sup>[6,86–88,114]</sup>. Flow in abdominal arteries is very often impaired. Sonography is of limited value because the imaging quality is often not good enough for decision making.

Aortography and intravascular ultrasound reveal two pathophysiological mechanism of branch vessel compromise associated with aortic dissection:

- (a) static narrowing of a branch artery and
- (b) dynamic narrowing of a branch artery.

Static narrowing occurs when the line of dissection intersects the vessel origin and the aortic haematoma has propagated into the vessel wall stenosing the side branch lumen. In dynamic obstruction the line of dissection spares the vessel but the dissection flap is positioned across the vessel origin like a curtain, or in other words, the flap spares the branch vessel wall but collapses across the branch vessel origin covering it like a curtain. Both mechanisms may be present in a given patient at the same time at different levels. Angiography may be necessary to identify these mechanisms, as interpretation of MRI or CT images may be difficult. Involvement of side branches of the aorta such as the coeliac artery, mesenteric or renal arteries can be detected with intravascular ultrasound<sup>[100,121]</sup>.

#### *Iliac and femoral artery involvement*

In aortic dissection without a distal tear (reentry) the aorta may become totally obstructed as the true lumen is compressed by the false lumen. The extent of the dissection can be visualized by CT or MRI. The true lumen is usually located anteriorly and the false lumen posteriorly. Angiography is necessary in order to visualize the full anatomical situation including collateral flow. In the future, MRI angiography may replace conventional angiography.

#### *Laboratory testing*

Laboratory testing plays a minor role when assessing acute aortic dissection, but it is useful to exclude other diseases. Often signs of inflammation with elevation of C-reactive protein are found.



**Table 12 Diagnostic imaging in acute aortic dissection**

Recommendation	Class I	IIa	IIb	III	Level of evidence
1. Transthoracic echocardiography followed by transoesophageal echocardiography	•				C
2. Computed tomography	•				C
• if detection of tears is crucial			•		C
3. Contrast angiography					
• to define anatomy in visceral malperfusion and to guide percutaneous interventions	•				C
• in stable patients		•			C
• routine preoperative coronary angiography				•	C
• in haemodynamically unstable patients			•		C
4. Magnetic resonance imaging		•			C
• in haemodynamically unstable patients				•	C
5. Intravascular ultrasound		•			C
• to guide percutaneous interventions			•		C

Beyond the acute situation, genetic testing of patients and relatives may be indicated. The identification of the FBN-1 gene leads to the development of two types of diagnostic tests: genetic family studies and mutation identification.

- (1) Family studies can be performed with specific FBN-1 polymorphic markers to identify the mutation-bearing haplotype<sup>[146,147]</sup>. These studies are only reliable in families with several affected individuals (at least four) as the involvement of a FBN-1 mutation (and not that of another gene) must be clearly demonstrated. Most families do not meet this requirement. Furthermore, the method is inappropriate in sporadic cases. In practice, these instances represent over 40% of the cases referred for biological diagnosis.
- (2) The second molecular test is mutation identification. This test should only be performed after the protein analysis or the previously mentioned family study has conclusively shown the presence of a FBN-1 gene defect. Mutation identification is very costly and time consuming. In fact, there is no quick and 100% reliable method to investigate a large gene, knowing that almost each family has its own specific defect and that the mutations are essentially point mutations. Finally, this very costly analysis may fail to identify a mutation since only the coding sequence and closely surrounding regions are investigated.
- (3) In all other instances and until better molecular tools are available, mutation identification cannot be performed on a systematic basis. However, in a few cases where the family mutation had been identified, it is possible to perform pre-natal diagnosis on chronic villus samples or offer diagnostic evaluation in children of affected subjects before symptoms set in<sup>[148,149]</sup>. There are also recent reports of preimplantation genetic diagnosis of Marfan's syndrome<sup>[150]</sup>.

In Ehlers-Danlos syndrome laboratory diagnosis is based on:

- (1) demonstration of structurally abnormal collagen type III by fibroblasts,

- (2) the identification of a mutation in the COL3A1 gene, or

- (3) linkage analysis with intragenic polymorphic markers<sup>[32]</sup>. The latter is difficult since mutations are private and widely distributed throughout this large and fragmented gene<sup>[32]</sup>. Furthermore, it must be noted that mutations within this gene are not specific since they are also found in patients with EDS types II (classical type mitis) and III (hypermobility type also associated with mutations in the COL5A1 or COL5A2 genes) which also display an autosomal dominant mode of inheritance. No phenotype-genotype correlations have been identified yet. The mutation therefore does not predict the disease type, course and severity. Finally, genetic heterogeneity has been reported<sup>[15]</sup>: a few patients with very similar recessively inherited clinical presentation, have apparently normal collagen III metabolism<sup>[19]</sup>.

In annuloaortic ectasia genetic heterogeneity and current technical shortcomings make genetic analysis difficult. Only two of the genes involved have been identified. Both are very large and there is no evidence to suggest a clustering of mutations within specific regions of these genes associated with dissecting aortic aneurysms. It is therefore unreasonable to screen these genes systematically. However, since antibodies are available against collagen III and fibrillin-1, structurally or metabolically abnormal proteins can be demonstrated in fibroblast cell cultures. These tests cannot be recommended as routine measures.

## Imaging modalities

Different direct and indirect methods as well as invasive and non-invasive techniques can be employed to diagnose aortic dissection (Tables 12, 13). The different imaging modalities are briefly described, taking into account technical considerations, specific diagnostic criteria, and the accuracy of the methods (Table 14).

**Table 13 Imaging in chronic aortic dissection**

Recommendation	Class I	IIa	IIb	III	Level of evidence
1. Magnetic resonance imaging	•				C
2. Transthoracic echocardiography followed by transoesophageal echocardiography		•			C
3. Computed tomography		•			C
4. Conventional angiography					
• to guide percutaneous interventions	•				C
• pre-operative diagnosis in selected patients		•			C
• for complete staging of the disease		•			C
5. Intravascular ultrasound					
• to guide percutaneous interventions		•			C

### *Transthoracic/transoesophageal echocardiography (TTE/TEE)*

#### *Technical considerations*

The aorta and the major aortic side branches can be studied using different scanning fields. It is important to use all scanning planes in order to provide complete information about the type and extension of aortic dissection. M-mode and two-dimensional echocardiography are taken in standard cross-sectional planes: parasternal, apical, subcostal scan fields. The ascending aorta is visualized in left parasternal projections. In aortic ectasia the right parasternal view and the apical view are useful. The aortic arch is best visualized via the suprasternal approach. Orthogonal and longitudinal scan planes can provide information concerning extension of dissection into the innominate artery, left common carotid or left subclavian artery. The descending aorta can occasionally be visualized in the left parasternal cross-sectional image and via specialized paraspinous scan fields obtained by imaging the patient through the back in the right decubitus position or by using abdominal scan planes<sup>[151–152]</sup>.

Transoesophageal echocardiography is performed with 3.5 and 7.0 MHz transducers which consist of 32, 64 or more elements mounted on the distal end of conventional 9 to 15 mm gastroscopes (echoscope). Single plane, biplane and multiplane transoesophageal echocardiographic probes are available. These new modalities allow visualization of the aorta in any given angle and therefore better special orientation<sup>[153]</sup>. On the basis of multiple tomographic cross-sectional images, 3-D reconstruction of the aorta can be performed<sup>[154]</sup>.

#### *Echocardiographic criteria of aortic dissection*

The diagnosis of aortic dissection is confirmed when two lumina separated by an intimal flap can be visualized within the aorta. Positive criteria are complete obstruction of a false lumen, central displacement of intimal calcification, separation of intimal layers from the thrombus, and shearing of different wall layers during aortic pulsation<sup>[6]</sup>. A tear is defined as a disruption of the flap continuity with fluttering of the ruptured intimal borders<sup>[3,6,94]</sup>. Smaller intimal tears can be detected by colour Doppler, registering jets transversing the

dissection membrane<sup>[94]</sup>. The number of tears is recorded and the location as well as the distance from the teeth to the tip of the probe is documented.

The differentiation in the true from the false lumen is based on M-mode, two-dimensional, and Doppler echocardiographic signs<sup>[155]</sup>. Criteria for identifying the true lumen are systolic expansion and diastolic collapse, the absence or low intensity of spontaneous echocardiographic contrast, systolic jets directed away from the lumen, and systolic forward flow, whereas criteria for the false lumen are diastolic diameter increase, spontaneous echocardiographic contrast, reversed, delayed, or absent flow and thrombus formation<sup>[6,155]</sup>. Flow signals within the false lumen represent signs of communication, whereas the absence of flow signals in multiple cross-sections means no communication. If the only communication is found distal to the beginning of the dissection, retrograde dissection can be assumed, which can be further differentiated into retrograde dissection with or without involvement of the ascending aorta<sup>[6]</sup>.

A thrombus is diagnosed when a mass separate from the intimal flap and the aortic wall is imaged in the free space of the false or rarely the true lumen<sup>[6]</sup>. Because thrombus formation depends on flow velocity, it may be graded to provide an estimate of the degree of communication<sup>[6]</sup>.

Echo-free spaces resulting from the presence of free fluid around the aorta are judged to be signs of penetration due to periaortic haematoma<sup>[6]</sup>. Additional mediastinal haematoma is assumed when the distance from the oesophagus to the left atrium or the aorta is increased (>1 cm) and pleural effusion is found. Pericardial effusion is considered to exist when an echo-free space between the epicardium and pericardium is present<sup>[6]</sup>.

Aortic regurgitation is diagnosed when disturbed diastolic flow signals are detected in the left ventricular outflow tract. Grading is performed by taking Doppler and colour Doppler echocardiographic criteria into account<sup>[156]</sup>.

#### *Accuracy of TTE/TEE*

The diagnosis of aortic dissection by standard transthoracic M-mode and two-dimensional echocardiography

is based on detecting intimal flaps in the aorta. Sensitivity and specificity of transthoracic echocardiography range from 77% to 80% and 93% to 96%, respectively, for the involvement of the ascending aorta<sup>[151,152,157]</sup>. However, in previous series, transthoracic echocardiography was successful in detecting a distal dissection of the thoracic aorta in only 70% of the patients<sup>[157]</sup>.

The value of transthoracic echocardiography is limited in patients with abnormal chest wall configuration, narrow intercostal spaces, obesity, pulmonary emphysema, and in patients on mechanical ventilation. These limitations prevent adequate decision-making, but have been overcome by transoesophageal echocardiography<sup>[6]</sup>.

Only experienced examiners should interpret echocardiographic studies. The European cooperative study group<sup>[3]</sup> showed that sensitivity of TTE and single plane, occasionally biplane, but not multiplane TEE reaches 99%, specificity 89% and positive predictive accuracy and negative predictive accuracy 89% and 99%, respectively. This was confirmed by others<sup>[158]</sup>. When the analysis was limited to patients who underwent surgery or autopsy, the sensitivity of TEE was only 89%, the specificity 88%, the positive predictive accuracy 97% and the negative predictive accuracy 93%<sup>[3]</sup>.

A problem exists in visualizing small circumscribed dissected segments within the distal part of the ascending aorta and the anterior portion of the aortic arch, which is known as the 'blind spot'<sup>[3]</sup>. This problem is caused by interposition of the trachea and the left main stem bronchus between the oesophagus and the aorta.

Artifacts due to reverberation within the lumen of the ascending aorta can be observed. These artifacts may present a problem to non-experienced observers<sup>[3]</sup> and may be the cause of the low sensitivity in one of the previous reports<sup>[159]</sup>.

By two-dimensional transoesophageal echocardiography, the intimal tear can be identified in 61% of patients. Doppler flow analysis has shown that not only uni-directional but also bi-directional flow occurs between the two lumina. Bi-directional flow is present in 75% of patients. By continuous wave Doppler a pressure gradient between the true and false lumen can be measured; it tends to be within the range of 10 to 25 mmHg<sup>[94]</sup>.

#### Summary

Transoesophageal echocardiography in addition to transthoracic echocardiography can be used for decision making in the emergency room or even operating theatre in acute aortic dissection with high accuracy. Pitfalls have to be taken into account. The high resolution enables the diagnosis also of intramural haematoma, plaque ulceration, as well as traumatic aortic injury. When more spatial resolution is necessary, CT or MRI are used in addition.

## Computed tomography

Since its introduction, helical CT has dramatically improved CT diagnostics because it minimizes motion artifacts and eliminates respiratory misregistration. With conventional CT, each cycle of the X-ray tube generates data which are used to reconstruct transaxial images. With helical CT, patient translation and X-ray exposure are simultaneous. This technique provides a data set acquired during a single breathhold. These data can be used to reconstruct 2-D and 3-D images in any plane. In fact, CT is currently the most commonly used imaging modality in patients with suspected aortic dissection<sup>[130]</sup>.

#### Technique of computed tomography

Imaging results depend on many factors, including X-ray beam collimation and table feed. The choice of the reconstruction interval is critically important to the success of the imaging procedure, and its settings are important in terms of spatial resolution. Reconstruction algorithms are highly critical to achieve optimal aortic imaging. Once transaxial images have been reconstructed, high quality 2-D reformations may be generated in desired planes (Multiplanar Reformation (MPR) Images). Maximum intensity projection images (MIPs) are generated by projecting imaginary X-rays through the 3-D matrix of interpolated images and mapping the maximum attenuation values along each ray to a gray scale image. This technique provides 'angiogram-like images'. Shaded surface display (SSD) images are generated after applying an arbitrary user-selected threshold. Voxels in the matrix of interpolated images are displayed as 3-D images, with depth perception added by shading from a virtual light source.

The basic setting comprises 3 mm collimation and 6 mm  $\cdot$  s<sup>-1</sup> table feed<sup>[137,138,160]</sup>. The start delay is determined by specific software which detects the contrast medium in a region of interest. 120 ml of low osmolar contrast medium is injected at a rate of 1–3 ml  $\cdot$  s<sup>-1</sup> with a power injector. Images are reconstructed at 2 mm intervals with overlap<sup>[137,138]</sup>. MPRs are generated in sagittal, coronal, oblique sagittal projections. MIP and SSD images are produced as an option. The first acquisition covers the thoracic aorta, a second acquisition with the same injection technique is necessary to examine the abdominal aorta and iliac arteries.

#### Diagnostic CT criteria for aortic dissection

The diagnosis is based on the demonstration of an intimal flap which separates the true from the false channel. The flap is identified as a low attenuation linear structure in the aortic lumen<sup>[137,160]</sup>. Secondary findings include internal displacement of intimal calcifications, delayed enhancement of the false lumen and aortic widening. MIP and MPR are useful both for making the initial diagnosis and for assessing the extent of the dissection. The technique can depict involvement of visceral as well as the iliac arteries.

Reported limitations to the interpretation of CT aortography are due to two artifacts: venous streaks and aortic motion artifacts. Venous streaks are easily identified because their orientation varies from slice to slice and extends beyond the limits of the aortic wall. Aortic motion artifacts are related to motion of the aortic wall, and particularly the intimal flap in the interval between the end of the diastole and the end of the systole. The use of a 180° linear-interpolation algorithm will clearly reduce or remove these artifacts. Mural thrombi in a fusiform aneurysm can be mistaken for aortic dissection. Structures or masses around the aorta may also make a diagnosis difficult.

#### *Accuracy of CT*

Sensitivities of 83%–94% and specificities of 87%–100% have been reported in the early 1990s in large prospective studies on the evaluation of aortic dissections with conventional incremental CT<sup>[3,137]</sup>. The benefits of helical CT compared to incremental CT are well established and include shorter examination times and the potential for better evaluation of the aorta, as all images are obtained during optimal contrast enhancement<sup>[137]</sup>. Artifacts are significantly reduced. The average sensitivity is better than 95%<sup>[137,138]</sup>. Sensitivity and specificity for diagnosing arch vessel involvement are 93% and 98% respectively, with an overall accuracy of 96%<sup>[137,138,160,161]</sup>.

#### *Summary*

CT is the technique used most often in patients with suspected aortic dissection.

The sensitivity is greater than 90%, specificity greater than 85%. The extent, localization and side branch involvement of aortic dissection can be assessed, signs of emergency detected. Limitations are related to diagnosis of aortic regurgitation, tear localization as well as detection of intimal tears and subtle /discrete aortic dissection (class 3).

### *Magnetic resonance imaging*

Although MRI is both highly sensitive and specific in diagnosing aortic dissection<sup>[137,138,161]</sup>, the technique is often not available on an emergency basis and examination of haemodynamically unstable patients may be difficult. However, in centres with experience in monitoring cardiac patients and even haemodynamically unstable patients on mechanical ventilation, MRI can be performed without complications<sup>[5]</sup>.

#### *Technique of MRI*

Whereas conventional spin-echo MRI and cine MRI require substantial imaging time to cover the entire aorta from the arch vessels down to the aortic bifurcation, new rapid scanning techniques permit image acquisition at multiple levels within a single breathhold. Thus,

imaging time is comparable to that required for performing a transoesophageal echocardiographic study. Even if sensitivity and specificity values are based on the experience gained with conventional MR-imaging sequences<sup>[160,161]</sup>, image quality is usually even better with breathhold imaging, and at least the same diagnostic accuracy can be expected. New real-time MR imaging sequences, which are available on the most advanced scanners, should further facilitate the diagnosis of aortic dissection in unstable patients<sup>[162]</sup>.

Another new MRI tool to image aortic dissection is three-dimensional contrast enhanced MR aortography. Images are similar to invasive aortography but the field of view is larger. Initial experience suggests that the diagnosis of aortic dissection can be made reliably<sup>[163,164]</sup>. Thus, a combination of MR aortography with cross-sectional MR images may be ideally suited to get both an overview of aortic anatomy (important for surgical planning) and details of the dissecting membrane and the aortic walls.

#### *Diagnostic MR criteria for aortic dissection*

MRI clearly demonstrates the extent of the disease and depicts the distal ascending aorta and the aortic arch in more detail than even transoesophageal echocardiography<sup>[165]</sup>. The localization of entry and reentry is nearly as accurate as with transoesophageal echocardiography, the sensitivity approaches 90%<sup>[165]</sup>. Accordingly, classification of the disease into proximal and distal aortic dissection which is crucial for selecting the appropriate management, can be easily accomplished with MRI. Adverse signs such as the presence of pericardial effusion or aortic regurgitation can be assessed accurately<sup>[160,166]</sup>. Flow in the false and true lumen can be quantified using phase contrast cine magnetic resonance imaging or by tagging techniques<sup>[167,168]</sup>. With state-of-the-art MRI, the proximal coronary arteries and their involvement in the dissecting process can be clearly delineated<sup>[169]</sup>. However, no direct comparison between imaging techniques regarding depiction of coronary involvement has been published yet.

#### *Accuracy of MRI*

Despite the accuracy of MRI, certain pitfalls and artifacts on MRI images need to be recognized and experience in reading MRI images of aortic dissection is essential<sup>[170]</sup>. Some kind of artifact may occur in up to 64% of patients but most of these artifacts are only seen in one section but not in the neighbouring ones. This observation facilitates the recognition of an artifact and distinguishes it from a pathological finding. Use of another imaging technique to make this distinction was required in only 2% of MR examinations. Awareness of the existence of artifacts, knowledge of normal anatomy, the use of axial images in all cases plus the addition of images in other planes as needed, rotation of phase and frequency gradients as needed, and clinical correlation may avoid misinterpretation in nearly all cases.



Magnetic resonance imaging permits detection of acute and subacute aortic intramural haemorrhages<sup>[90,171]</sup>. Typical features of intramural haemorrhage include a thickened wall (>7 mm) with a smooth surface which may contain areas of high signal intensity. The high signal intensity is the result of methemoglobin formation which occurs after several days and persists for several months, although it may be absent in the acute phase<sup>[171]</sup>. Because intramural haemorrhage of the thoracic aorta may be associated with true dissection of the abdominal aorta, the latter should also be evaluated. Magnetic resonance imaging could not detect subtle degrees of dissection — in a small series of cases neither did CT or TOE<sup>[89]</sup>. But plaque rupture can be visualized with high accuracy, as well as traumatic iatrogenic dissection.

#### Summary

MRI has the highest accuracy and sensitivity as well as specificity (nearly 100%) for detection of all forms of dissection (class 1, 2 and 4, 5) except subtle/discrete forms (class 3). Distribution and availability is limited particularly in emergency situations. Most often MRI is used in stable haemodynamic conditions and chronic aortic dissection for follow-up. MRI provides excellent visualization of tear localization, aortic regurgitation, side branch involvement and complications.

### Aortography

Retrograde aortography was the first accurate diagnostic tool to assess patients with suspected aortic dissection. The diagnosis of aortic dissection was first reported by Robb and Steinberg in 1939 and it became routine in the 1960s<sup>[172,173]</sup>. Thereafter, aortography was considered for several decades as the diagnostic standard for the evaluation of aortic dissection<sup>[174]</sup>. However, because other accurate methods for the antemortem diagnosis of aortic dissection were not yet available, the low sensitivity of angiography was accepted.

#### Technique of aortography

To visualize the signs of aortic dissection, injections of adequate amounts of contrast media (40–50 ml at 20–25 ml · s<sup>-1</sup>) at different levels and using different projections are usually required, to best define the thoracic aortic anatomy in each individual patient<sup>[175,176]</sup>. The transit of the contrast material along the aorta can be followed. Special care is to be taken to fully opacify the proximal aspect of the brachiocephalic trunk and to use appropriate projections<sup>[176]</sup>. For abdominal aortography, a single injection of 40 ml of contrast agent at a rate of 20 ml · s<sup>-1</sup> is generally adequate for posteroanterior projections, but biplane angiography is required particularly for the visualization of entry/reentry tears and in order to meet the demands of interventional radiol-

ogists. Rarely, angulated views are required to depict the ostia of some abdominal side-branches. Alternatively, intravenous aortography with digital subtraction may be performed by injecting contrast material into the antecubital vein or directly into the right atrium or superior vena cava<sup>[175]</sup>. This technique is less invasive and requires smaller amounts of contrast media but it usually provides lower resolution images than conventional angiography.

#### Diagnostic aortography: criteria for aortic dissection

The angiographic diagnosis of aortic dissection is based upon 'direct' (diagnostic) angiographic signs, such as the visualization of the intimal flap (negative, often mobile, linear image) or the recognition of two separate lumens, or 'indirect' (suggestive) signs, including aortic lumen contour irregularities, rigidity or compression, branch vessels abnormalities, thickening of the aortic walls and aortic regurgitation<sup>[157]</sup>. Aortography is able to localize the site of origin of the dissection<sup>[175]</sup>. The true lumen is typically compressed and tends to adopt a spiral shape. Injections in the false lumen are characterized by the absence of branch vessels or the characteristic sinus of Valsalva configuration and late filling or staining with contrast<sup>[176]</sup>. Contrast aortography accurately identifies branch vessel involvement<sup>[176]</sup>. It is mandatory to rule out this complication in patients with neurological symptoms, acute renal failure, hypertensive crisis or mesenteric/limb ischaemia. Peripheral pulse deficits can provide important diagnostic clues. In particular, angiography is an excellent technique to define renal or mesenteric compromise<sup>[177]</sup>. The occurrence of associated aortic regurgitation and its severity may be readily recognized during aortography. However, this technique has recently been replaced by other new imaging modalities with respect to its ability to evaluate the precise mechanism of aortic regurgitation. In some patients, however, angiography may reveal widening of the aortic root, displacement of a valve cusps or even prolapse of an intimal flap into the left ventricle as the underlying mechanism<sup>[178,179]</sup>. Aortography may also demonstrate aortic wall rupture into the pericardial cavity, right atrium, left atrium, right ventricle and pulmonary artery<sup>[179]</sup>.

#### Accuracy of aortography

The specificity of aortography for diagnosing aortic dissection is better than 95% but its sensitivity may be lower than that of other techniques, especially in atypical forms of aortic dissection<sup>[178]</sup>. In the European cooperative study, the sensitivity and specificity of aortography for the diagnosis of aortic dissection was 88%<sup>[3]</sup>. False-negative aortograms are mainly the result of the inability of the technique to differentiate the two classic lumens within the aorta<sup>[3,6,153,180,181]</sup>. Aortograms yielded false-negative results in 15 of 65 consecutive patients with proven aortic dissection (sensitivity 77%)<sup>[182]</sup>. The missed diagnosis was due to a completely thrombosed false lumen or intramural haematoma in 13 patients, and to a large ascending aortic aneurysm with

nearly equal and simultaneous opacification of the false and true lumen<sup>[182]</sup>. Aortography may be somewhat more useful in the diagnosis of aortic dissection with thrombosis of the false lumen than in typical intramural haematoma, because in the former some degree of lumen compromise is the rule, whereas the aortic lumen usually remains unaffected in the latter<sup>[153]</sup>. Nevertheless, despite some limitations, angiography remains a widely available technique in most centres, and many cardiac surgeons feel comfortable with the information it provides. This is mostly the consequence of the vast experience with this technique.

Aortic intramural haematoma (class 2 dissection) has been considered the principal reason for false-negative findings on aortography. A faint shadow corresponding to the vascular silhouette may appear well separated from the aortic lumen and this pattern may be indicative of an intramural haematoma. Straightening of the lumen, mild luminal narrowing, or irregularities may give some diagnostic clues for a subtle class 3 aortic dissection. Multiple views of the ascending aorta on aortography may provide further diagnostic information<sup>[89,104,182]</sup>. In patients with suspected aortic dissection based on the clinical history, aortography should be performed when non-invasive techniques are negative.

In class 4 aortic dissection, penetrating atherosclerotic ulcers of the distal descending aorta can be diagnosed with angiography, but biplane angiography has to be used<sup>[105,106]</sup>. Penetration surpassing the intima may lead to medial haematoma, penetration to the media may cause pseudoaneurysm and penetration disrupting the adventitia results in aortic rupture; all these signs may be detected by angiography<sup>[106]</sup>.

#### *Limitations of aortography*

Some limitations of this technique should be recognized. It is invasive and therefore has an inherent risk. The advancement of catheters should be performed with care and only by experienced angiographers. Forceful pushing of the catheter or the guidewire should be strongly discouraged to avoid injury, particularly if the catheter is located within the false lumen. Pressure measurements and manual injections of contrast media may be helpful to differentiate between the true and false lumen. Once the correct position of the catheter is demonstrated catheter exchanges should be performed using long exchange wires. In addition, this technique requires the administration of potentially nephrotoxic radiopaque contrast media and ionizing radiation. Furthermore, the intimal flap as well as the distal end of the dissection are not clearly defined when slow flow is present. It is important to emphasize that aortic wall thickness cannot be accurately visualized. Aortography may underestimate the luminal size in the presence of non-opacified thrombus formation<sup>[182]</sup>. In critically ill patients the time required for assembling the angiographic team, bringing the patient to the angiographic suite and the duration of the procedure itself may be too long to be justified. This should always be taken into account as diagnostic delays are associated with an increased mortality<sup>[183]</sup>.

#### *Coronary angiography*

In some patients delineation of coronary anatomy is desirable prior to surgical repair. Although new imaging techniques are gaining an emerging role in the assessment of coronary ostial involvement by the dissecting flap, coronary angiography remains the gold standard in the evaluation of the whole coronary tree<sup>[144,145]</sup>. This is important because chronic coronary atherosclerotic disease (present in 25% of patients) — although not related to the process of aortic dissection — may worsen the surgical outcome. This is a strong argument used by some authors to recommend coronary angiography for all stable patients. However, whether or not selective coronary angiograms should be performed in patients being considered for surgical repair remains undetermined<sup>[145]</sup>. Mortality after surgery for aortic dissection does not seem to be related to myocardial ischaemia and, therefore, it is unlikely that systematic coronary angiography prior to surgical repair can influence outcome. It should be left up to the clinical judgment of the physician and surgeon whether coronary angiography is to be performed.

#### *Summary*

Aortography is highly valuable to diagnose classical aortic dissection, but limitations are obvious in dissection subtypes such as non-communicating aortic dissection and intramural haematoma and haemorrhage formation (class 2) as well as plaque rupture (class 4). Aortography is the standard technique for guiding interventions in aortic dissection.

### *Intravascular ultrasound*

#### *Technique of intravascular ultrasound*

To perform an intravascular ultrasound (IVUS) examination, disposable catheters are advanced under fluoroscopy over conventional guidewires with/without guiding catheters. The procedure can be performed safely in less than 10 min<sup>[100,101]</sup>. Because of the well-known trade-off between frequency and penetration, transducers with <20 MHz are preferred, but such transducers cannot be advanced via guiding catheters (6–8F). The size of 10 MHz transducers reaches 8.2F (3.3 mm). These transducers are advanced over 0.35 inch wires. In regions with aneurysmal dilation the whole aorta cannot be displayed from a single position, when 20 or 30 MHz transducers are used. This has been overcome by 10 MHz transducers. It is difficult to align the catheter coaxially within the lumen of the aortic arch. Prototype flexible catheters which can maintain a pre-selected curvature (steerable) are currently under investigation<sup>[184]</sup>. Catheters have been developed which allow Doppler, tissue Doppler and 2nd harmonic imaging<sup>[185]</sup>.

**Table 14 Comparing the diagnostic value of imaging techniques in aortic dissection**

	TTE/TEE	CT	MRI	Angiography	IVUS
Sensitivity	++	++	+++	++	+++
Specificity	+++	++	+++	++	+++
Classification	+++	++	++	+	++
Tear localization	+++	-	++	+	+
Aortic regurgitation	+++	-	++	++	-
Pericardial effusion	+++	++	++	-	-
Mediastinal haematoma	++	+++	+++	-	+
Side branch involvement	+	++	++	+++	+++
Coronary artery involvement	++	-	+	+++	++
X-ray exposure	-	++	-	+++	-
Patient comfort	+	++	+	+	+
Follow-up studies	++	++	+++	-	-
Intra-operative availability	+++	-	-	(+)	(+)

TTE/TEE=transthoracic/transoesophageal echocardiography.

CT=computed tomography.

MRI=magnetic resonance imaging.

IVUS=intravascular ultrasound.

#### *Diagnostic IVUS criteria for aortic dissection*

The use of intravascular ultrasound (IVUS) has been advocated to complement angiographic information in the diagnosis of patients with aortic dissection<sup>[100,121]</sup>. During a cardiac catheterization procedure, this technique can overcome most of the potential limitations and pitfalls of conventional angiography. IVUS directly visualizes the vessel wall architecture from inside the aortic lumen. It therefore allows the accurate recognition of aortic wall characteristics and pathology, and completes the indirect information of 'the lumen shadowgram' depicted by contrast angiographic techniques.

#### *Accuracy of IVUS*

In patients with classic forms of aortic dissection this catheter-based imaging tool provides crisp visualization of the intimal-medial flap, its movement (pulsatility), its circumferential and longitudinal extent and the degree of luminal compromise. This technique appears particularly well suited to delineate the most distal extent of abdominal aortic dissections<sup>[100,121]</sup>. Sensitivities and specificities of close to 100% have been reported<sup>[121]</sup>. The shape of the true and false lumen is readily displayed, whereas false lumen thrombosis is detected with a higher sensitivity and specificity than with transoesophageal echocardiography<sup>[121]</sup>. IVUS may also help to distinguish the true from the false lumen when it is difficult to make this distinction. It has been suggested that the three-layered appearance of the intact normal aortic wall may be differentiated from the single-layered appearance of the outer wall of the false lumen. In addition, cobwebs may be identified in the false lumen in some patients. Branch involvement appears to be better defined with IVUS than with transoesophageal echocardiography (blind spot in the ascending aorta and the anterior portion of the arch, abdominal vessels) or with computed tomography<sup>[121]</sup>. In addition, the precise mechanism of vessel compromise (dissection intersecting

and narrowing the vessel origin versus ostium spared by the dissection but covered by a prolapsing flap) may be clarified by IVUS<sup>[100,101,121]</sup>. Precise delineation of the entry tears is difficult, however, this may be seen more frequently in the abdominal aorta than in the thoracic aorta<sup>[100]</sup>. The lack of Doppler capabilities is still a drawback of the technique. Thrombus formation within the false lumen may be predicted by the appearance of spontaneous echo-contrast.

Changes in the aortic wall due to haemorrhage into the media are visible by IVUS because of the accompanying increase in wall thickness<sup>[100,101]</sup>. IVUS is very accurate in displaying the circumferential and longitudinal extent of the haematoma. Aortic haematomas appear as crescent-shaped or circumferential thickening of the aortic wall<sup>[121]</sup>. In some segments, an echo-free space is visualized, yielding atypical image of a layered aortic wall<sup>[100,101,121]</sup>. In other areas, speckled granular reflections are recognized within the aortic wall. The shape of this intramural haemorrhage may be concentric and affect the complete aortic circumference, but it is typically limited to a segment of the aorta. IVUS appears particularly useful to rule out the presence of pulsatile intimal flaps and deeply penetrating atherosclerotic ulcers, when others techniques give inadequate results. In addition, it appears particularly attractive for patients with suspected aortic dissection and a normal aortography<sup>[121]</sup>.

## **Surgical and interventional therapy**

### *Surgical therapy*

#### *Introduction*

The aim of any surgical intervention in type A (type I, II) aortic dissection is the prevention of aortic rupture or of the development of pericardial effusion which may lead to cardiac tamponade. It is also imperative to eliminate aortic regurgitation and to avoid myocardial

**Table 15 Surgical therapy of acute type A (type I and II) aortic dissection**

Recommendation	Class I	IIa	IIb	III	Level of evidence
1. Emergency surgery to avoid tamponade/aortic rupture	•				C
2. Valve-preserving surgery — tubular graft <i>if</i> normal sized aortic root and no pathological changes of valve cusps	•				C
3. Replacement of aorta and aortic valve (composite graft) <i>if</i> ectatic proximal aorta and/or pathological changes of valve/aortic wall	•				C
4. Valve-sparing operations with aortic root remodelling for abnormal valves		•			C
5. Valve preservation and aortic root remodelling in Marfan patients		•			C

**Table 16 Surgical therapy of acute type B (type III) aortic dissection**

Recommendation	Class I	IIa	IIb	III	Level of evidence
1. Medical therapy	•				C
2. Surgical aortic replacement <i>if</i> signs of persistent or recurrent pain, early expansion, peripheral ischaemic complications, rupture	•				C
3. Surgical or endovascular fenestration and stenting <i>if</i> persisting mesenteric, renal or limb ischaemia or neurologic deficits		•			C

ischaemia. In type B (type III) dissection it is the main goal to prevent aortic rupture. One should always aim to resect the intimal tear in class I dissection. Whereas in aortic dissection limited to the ascending aorta with or without involvement of the aortic arch, the resection of the entire intimal flap may be possible, a full repair of the aortic dissection is rarely reached in type A and type B (type I–III) dissection (Tables 15, 16). Various approaches to the repair of the acutely dissected aorta have been suggested. This fact sheds light on the remarkable methodologic variability<sup>[186–190]</sup>.

#### *The proximal aorta in acute type A (type I and II) aortic dissection*

Two key questions need to be answered prior to deciding on the most appropriate technique for repairing an acute type A (type I, II) dissection: what is the size of the aortic root and what is the condition of the aortic valve? If the ascending aortic and aortic root diameters are normal without downstream displacement of the coronary ostia, and with no commissural detachment of the aortic valve leaflets or other acute or chronic pathological changes of the leaflets, a tubular graft is usually anastomosed to the sinotubular ridge (Table 15). Whenever one or more commissures are detached, the valve needs to be resuspended prior to graft insertion. If valve reconstruction appears unsafe, or if obvious congenital or acquired abnormalities are present, it is generally better to replace the valve before a supracommissural graft is inserted. However, the repair of bicuspid valves has been reported<sup>[191]</sup>.

The standard approach to the ascending aorta and transverse aortic arch in aortic dissection type A (type I, II) is through median sternotomy. The pericardial incision is started in the midline inferiorly in order to avoid the dissected and therefore friable ascending aorta. Once

the patient is on extracorporeal circulation, which is usually established after cannulation of one femoral artery and the right atrium, the aorta is mobilized for visualization of the origin of the innominate artery and the aortic root. If the aortic arch is to be replaced, surgical dissection proceeds along its anterior aspect and the origins of the arch branches are prepared.

An acute type A (type I, II) dissection in a previously ectatic proximal aorta requires a different approach. In such instances — this includes most patients with Marfan's syndrome — implantation of a composite graft (aortic valve plus ascending aortic tube graft) is recommended<sup>[192,193]</sup>. In the original method described by Bentall and De Bono, the coronary ostia remain in continuity with the 'old' aorta and are anastomosed directly to the ascending portion of the graft after valve implantation<sup>[194]</sup>. If the coronary ostia are close to the aortic annulus and if a stiffened aortic wall creates tension on the ostia when they are relocated to the graft, they may be excised in button form before being anastomosed<sup>[195]</sup>. Implantation of allografts and xenografts should be restricted to elderly patients or special other indications since late postoperative degeneration may require reoperation on the aortic root. More recently, valve sparing operations and/or aortic root remodelling have been suggested even in the emergency situation of an acute type A (type I, II) dissection<sup>[196,197]</sup>. As these procedures are more complicated and time consuming than composite grafting, they should only be performed by surgeons who have broad experience with such procedures in elective cases.

The distal connection of the tube graft is made to the uninvolved ascending aorta in those relatively rare cases of limited type A (type II) dissection. In all other patients, replacement is carried to the junction of the ascending aorta and arch or beyond that level.



Technical considerations for the management of the dissected non-ectatic aortic root first address the condition of the aortic valve commissures (Table 15, 16) as well as the presence and extent of the dissection in relation to the coronary ostia. If the dissection has reached either ostium without disrupting the coronary vessel, the ostium can usually be preserved. An ostium completely surrounded by dissected aortic wall may be excised in button form. The dissected layers around the ostium are conjoined using tissue adhesive and over-and-over suturing before the anastomosis to a tube graft is accomplished. Bypass grafting of coronary arteries using saphenous vein segments is limited to those instances where a small torn ostium with irreparable damage precludes secure reconstruction.

The creation of a firm and leak proof seat of the ascending aortic graft on the acutely dissected proximal aorta is accomplished by use of teflon felt, tissue adhesive such as gelatin resorcinol formaldehyde glue (GRF-glue) or both<sup>[198,199]</sup>. Regardless of which method is applied, the dissected portion of the aorta is first completely divided at the level of the sinotubular junction. Traditionally, the layers of the aorta are then conjoined by sandwiching them between strips of teflon felt placed inside and outside the dissected perimeter of the vessel. This technique is now gradually replaced by glue reconstruction of the dissected layers, a technique which has turned out to be technically easier and time saving<sup>[198]</sup>. Application of GRF glue not only produces a firm union of the dissected layers but also converts them to a leather like texture. This facilitates secure reconstitution of the aortic root greatly, while it obliterates any dead spaces below the anastomosis between graft and aorta at the same time. With either technique employed, detachment of valve commissures may require resuspension by the use of pledgetted transmural mattress sutures in addition to reconstruction of the dissected wall layers.

#### *The proximal aorta in chronic type A (type I and II) aortic dissection*

As in acute dissection, the choice for the type of proximal repair in chronic dissection depends on the constitution of both the aortic root and the valve. In cases where the root is of normal configuration and the valve is intact, a supracommissural graft may be implanted. Once the commissures are found to be detached, resuspension of one or more leaflets is necessary. This represents an adequate valve repair in about 50% of patients with chronic type A dissection<sup>[199]</sup>. In every other case the valve should be replaced before the vascular graft is implanted.

If the entire root is aneurysmatic, a more radical approach is advisable to prevent late dilatation and recurrent dissection of the remaining aorta. In such instances a composite graft should be implanted since it eliminates the entire diseased proximal aortic portion. As an alternative, xenografts, allografts or autografts may be implanted in selected cases. The valve sparing

operations mentioned above are another option. They may be indicated in root ectasia. A basic consideration to be applied to these procedures is that aortic incompetence commonly results from dilatation of the sinotubular ridge rather than the annulus<sup>[200]</sup>. The aorta is fully divided 5 mm above the valve commissures and the leaflets are examined for symmetry and absence of organic disease<sup>[196]</sup>. In David's techniques the coronary sinuses and the coronary ostia are excised leaving the valve cusps and their insertion lines intact. As the next step a mattress suture is passed through the apex of each commissure before transmural mattress sutures are placed through the aortic annulus. The annular sutures are then passed through the cardiac end of a prosthetic graft and the aortic valve remnants are drawn into the graft before they are sewn to it from the inside<sup>[196]</sup>.

Another valve remodelling procedure is less radical: only the Valsalva sinuses are replaced, and the ventricular outflow diameter is left at its given size<sup>[197]</sup>. The aortic sinuses are removed leaving a 3 mm rim along either side of the line of insertion of the cusp intact. The cardiac end of an ascending aortic graft is then scalloped in such a manner as to accept the triangles of the excised valve attachments. Next, the strips of aortic wall from where the cusps arise are sutured to the edges of these triangles before the previously excised coronary buttons are connected to appropriate windows in the graft<sup>[197]</sup>. Whenever the valve may not be preserved and the aortic root is ectatic, composite grafting as described above has remained the standard method for total root replacement in chronic aortic type A dissection.

#### *The aortic arch in acute type A (type I and II) dissection*

Treatment of the acutely dissected aortic arch remains a much debated subject. The discussion is centred around the question of when and to what extent the arch should be replaced. At present there is broad consensus that any dissected arch should be explored during a short period of hypothermic circulatory arrest. In the absence of an arch tear an open distal anastomosis of the graft and the conjoined aortic wall layers at the junction of the ascending and arch portions is made<sup>[201,202]</sup>. Arch tears occur in up to 30% of patients with acute dissection<sup>[203,204]</sup>. If an entry tear traverses the aortic arch, the distal graft to aortic anastomosis is usually made in such a manner as to replace the arch beyond the entry bearing portion. Whenever extensive tears are found, which continue beyond the junction of the transverse and descending aortic segments, or when there is acute dissection of a previously aneurysmatic arch, subtotal or total arch replacement may be required. This may have to include reconnection of some or all supraaortic vessels to the graft during hypothermic circulatory arrest. The techniques for reconstituting and fortifying the dissected layers of the aortic arch are similar to the ones described for the aortic root; either GRF adhesive or strips of teflon felt are used.

### *The aortic arch in chronic type A (type I and II) aortic dissection*

The procedure on the aortic arch is often less demanding in chronic dissection than in acute dissection because the extent of the aneurysmal dilatation generally dictates the extent of aortic replacement. Beyond that collagen ingrowth will improve the wall quality of the false lumen over time, making it possible to suture it to the graft if required. As in acute arch dissection, the graft is better connected to the true channel of the aorta either at the distal end of its wall delamination or beyond any entry tears present in the arch, and thereby reconstituting the wall layers at this level. If this is not feasible under certain conditions, the anastomosis is made to the firm wall of the false channel. Late aneurysm formation is always a possibility in such cases. However, in replacement procedures extending to the proximal descending aorta, the graft is usually anastomosed to the outer aortic wall because redirecting distal blood flow to the true aortic channel does not serve any purpose in view of the presence of multiple downstream reentries. In arch aneurysms extending to the downstream aorta an elephant trunk extension of the arch graft is inserted as first described by Borst *et al.*<sup>[205,206]</sup>. Total aortic arch replacement using this technique includes the division of the dissected circumference of the distal aorta and the removal of the downstream dissecting membrane. This technique greatly facilitates later procedures on the downstream aorta. Instead of performing a conventional anastomosis between the end of the graft and the descending aorta, the graft is allowed to float freely in the aortic lumen. During the subsequent procedure the elephant trunk section of the graft may either be connected to the distal descending portion directly or it is extended with another tubular prosthesis, which may then be anastomosed at any desired downstream level of the aorta.

#### *Summary*

Surgery in acute type A (type I and II) dissection. The aim of surgery is to prevent aortic rupture, pericardial tamponade, and to relieve aortic regurgitation. Implantation of a composite graft in the ascending aorta with or without reimplantation of coronary arteries is performed. A large variability of surgical procedures exist.

### *Surgery in type B (type III) aortic dissection*

There is still a broad consensus that the indications for operative treatment in patients with acute type B (type III) are limited to the prevention or relief of life threatening complications such as intractable pain, a rapidly expanding aortic diameter, periaortic or mediastinal haematoma as signs of aortic rupture. Dissection occurring in a previously aneurysmatic aorta may also be considered a surgical emergency. The onset of other complications such as ischaemia of limbs, kidneys or gut

may warrant timely interventional therapy by catheter guided fenestration of the dissection membrane thereby decompressing the true lumen of the abdominal aortic segment. In case this procedure does not lead to prompt relief of symptoms, surgical intervention is required. All other, uncomplicated type B (type III) aortic dissections are usually treated conservatively, since till today there is no proven superiority of one particular treatment above another, be it surgical, interventional by stent grafting or medical.

Operative intervention for chronic type B (type III) aortic dissection is primarily directed to alleviate the expansion process and to the threatening or manifest rupture of the dissected segment. Indications for operative intervention for post-dissection aneurysms are similar to those of other thoracoabdominal aneurysms.

The surgical management of both acute and chronic dissections of the descending aorta comprises the replacement of affected portions with a tubular graft of appropriate length and size. The standard approach to the dissected descending aorta is the conventional fifth rib posterolateral chest incision which allows access to replace the descending aorta down to the level of the eighth intercostal space. According to the extension of the vessel disease, this incision gives appropriate exposure of the aorta either through a single or double thoracotomy. Most surgeons perform the operation using extracorporeal circulation by means of a left heart bypass. In cases where the replacement has to be extended toward the thoracoabdominal segment, femorofemoral bypass may be preferred.

Usually moderate hypothermia is induced with care being taken to equalize perfusion pressures during the implantation of the graft proximal and distal to the aortic crossclamp.

#### *Summary*

Surgery in acute type B (type III) dissection. The indication for surgery in type B (type III) aortic dissection is limited to the following criteria

- persistent, recurrent chest pain
- aortic expansion
- periaortic haematoma
- mediastinal haematoma

#### *Management in infancy and childhood*

The same principles used for adults apply to the management of dissection and aneurysm in infancy and childhood. There are no measures specific for this age group. It is thought that dissection will inevitably occur whenever a part of the arterial tree reaches critical dimensions, just as it holds true for those who have reached skeletal maturity. The major area of controversy remains when to intervene prophylactically in order to prevent dissection when there is underlying dilatation. Is the absolute dimension of the aneurysmal segment the most useful measure, or should a size ratio be used as

**Table 17** *Interventional therapy in aortic dissection*

Recommendation	Class I	IIa	IIb	III	Level of evidence
1. Stenting of obstructed branch origin for static obstruction of branch artery		●			C
2. Balloon fenestration of dissecting membrane plus stenting of aortic true lumen for dynamic obstruction		●			C
3. Stenting to keep fenestration open		●			C
4. Fenestration to provide re-entry tear for dead-end false lumen		●			C
5. Stenting of true lumen					
● to seal entry (covered stent)			●		C
● enlarge compressed true lumen		●			C

has been proposed for the root<sup>[41,207,208]</sup>. What are appropriate upper limits to be used in a growing child to define these parameters? These factors have yet to be agreed.

### *Interventional therapy by percutaneous stenting and/or percutaneous fenestration*

#### *Introduction*

Conventional treatment of type A (type I, II) dissection consists of surgical reconstruction of the ascending aorta with restoration of flow, preferentially into the true lumen. In type B (type III) dissection with ischaemic complications, treatment includes reconstruction of the thoracic aortic segment containing the entry tear<sup>[209]</sup>, bypass of the compromised organ or limb<sup>[210]</sup> or surgical fenestration<sup>[211–213]</sup>. Four major patterns of ischaemic complications can be distinguished, depending on the characteristics and course of the true and false lumen as well the major aortic branches involved:

- Compression of the true lumen in the region of the main abdominal branches.
- Compression of the true aortic lumen proximal to the main abdominal branches.
- Involvement of aortic main branches in the dissection.
- Enlarging false aneurysm due to patent proximal entry tear.
- Treatment includes reconstruction of the thoracic aortic segment containing the entry tear<sup>[209]</sup>, bypass of the compromised organ or limb<sup>[210]</sup> or surgical fenestration<sup>[211–213]</sup>.

Approximately 90% of peripheral pulse deficits associated with aortic dissection can be reversed by repairing the thoracic aorta<sup>[214]</sup>. However, patients with mesenteric or renal ischaemia do not fare that well. Mortality of patients with renal ischaemia is 50 to 70%<sup>[210,212]</sup> and mortality figures in mesenteric ischaemia can be as high as 87%<sup>[210]</sup>. The surgical mortality rates in patients with peripheral vascular ischaemic complications, however, also amounts to up to 87% of those with mesenteric ischaemia<sup>[209,210,213,215]</sup>, with an 89% hospital mortality rate<sup>[212,213]</sup>. The operative mortality of surgical fenestration is only 21% to 67%, and percutaneous management of obstructed branch arteries has therefore recently been

proposed<sup>[212,213]</sup>. The first successful endovascular balloon fenestration of a dissecting descending aortic membrane to treat mesenteric ischaemia was described in 1990<sup>[216]</sup>. Various reports have been published since<sup>[217–224]</sup>.

Aortic stent grafts were first used to exclude abdominal and later thoracic true and false aneurysms<sup>[225–228]</sup>. The treatment of aortic dissection evolved slowly, however, because the risk of paraplegia was feared. This complication occurs in up to 18% after surgery<sup>[229–231]</sup>. However, with further technical improvement a large series of aortic dissection cases has now been successfully treated by stent grafts which cover the entry tear in the descending aorta and even in the aortic arch<sup>[232]</sup>. Moreover the authors demonstrated that the closure of the entry tear is essential to reduce aortic size. Entry tear closure promotes both thrombus formation and healing<sup>[232]</sup>. Combined surgical and interventional procedures have been proposed already<sup>[233]</sup>.

### *Indications for stent placement and fenestration*

The exact role of percutaneous fenestration and stent placement in the treatment of aortic dissection has yet to be determined (Table 17). However, there appears to be a clear-cut indication for fenestration and stent placement in the treatment of static or dynamic obstruction of aortic branch arteries.

- Vessels compromised by static obstruction of a branch artery are treated by placing endovascular stents across the vessel origin.
- Vessels compromised by dynamic obstruction are treated by percutaneous balloon fenestration with or without stents in the aortic true lumen.

In classic aortic dissections, successful fenestration raises true luminal pressure but leaves false luminal pressure unchanged. Sometimes stents have to be deployed in the true lumen in order to buttress the flap in a stable position remote from branch artery origins<sup>[223]</sup>. In chronic dissection where fenestration of a fibrosed dissecting membrane may result in collapse of the connection between true and false lumen, a stent may be necessary to keep the fenestration open<sup>[234]</sup>. A second indication for fenestration is to provide a reentry tear for the dead-end false lumen back into the true lumen. The

aim of this is to prevent thrombosis of the false lumen which might compromise branches which derive their supply exclusively from the false or jointly from the false and true lumen. There are autopsy studies that noted improved survival in acute classical dissection in patients with reentry tears versus those without<sup>[235]</sup>. On the other hand, this treatment may increase the risk of aortic rupture in the long-term because a large reentry tear promotes flow in the false lumen, a fact which provides the basis for aneurysmal degeneration of the false lumen<sup>[211,223]</sup>. There is also a certain risk of peripheral embolism from a patent but partly thrombosed false lumen<sup>[211,223,234]</sup>.

The most effective and optimal method to exclude the aneurysmally dilated false lumen would be the exclusion of the proximal entry tear with an acceptable stent graft. In such cases the absence of a distal reentry tear is desirable<sup>[236]</sup>, and local treatment by fenestration and stents serves only to establish flow to compromised aortic branches which originate from the false lumen.

Compression of the true aortic lumen cranial to the main abdominal branches with secondary distal ischaemic changes because a narrowed true lumen is another indication for stent placement. The stent will enlarge the compressed true lumen and improve blood flow<sup>[224,234]</sup>. Fenestration and pressure reduction within the false lumen still seems to be the optimal choice, however<sup>[218]</sup>.

### *Interventional techniques*

#### *Technique of percutaneous balloon fenestration*

The technical goal in percutaneous balloon fenestration is to create a tear in the dissection flap that separates the true from the false lumen. It is preferable to perform fenestration from the smaller (usually the true lumen) into the larger or false lumen. Most commonly a Roesch-Uchida needle, Brockenborough needle or Colopinto needle is used to perform fenestration<sup>[219,224,234,236]</sup>. The fenestration site is chosen close to the arteries to be salvaged. After the needle is advanced from the true into the false lumen at the desired level—this is very much facilitated by IVUS monitoring—and following safe placement of a super stiff guidewire into the false lumen, angiography is performed in both lumina. A balloon catheter of 12 to 15 mm diameter and 20–40 mm length is used to create a transverse tear. If IVUS is not available, a balloon catheter or a Dormia basket placed in the false lumen can be used as a targeting object for piercing the dissecting membrane with the needle<sup>[220]</sup>. It may be necessary to implant large stents in the range of 10–14 mm diameter in order to keep the aorta or side branches open, particularly when the false lumen has already been thrombosed.

#### *Technique of aortic stenting*

Aortic stents are primarily used to supplement fenestration as well as to reduce the dissection flap. In case of

high grade compression of the supplying true lumen cranial to major aortic branches, the compressed lumen may be enlarged by a stent to increase distal flow.

The so called ‘Harrington road’ approach implies the placement of telescoping stents into the true lumen from the entry tear near the left subclavian artery all the way down past the visceral arteries, and across the bifurcation, if necessary. This approach is expensive, however, and if multiple branch origins are covered by stents, the patient is exposed to a long-term risk of branch artery stenosis or distal embolization. Multiple aortic stents separated by a certain distance are used unless there is a large pressure gradient between the true and false lumen<sup>[223]</sup>. Sometimes stents have to be placed across the origin of the celiac, superior mesenteric and renal arteries to keep the supplying true lumen patent<sup>[236]</sup>. Long-term follow-up following these complex interventions is not yet available.

A more sensible method seems to be the creation of a large reentry tear where it is needed, followed by stent placement between the tear and the compromised branch. In order not to compromise flow to the distal branches, stent placement across the superior mesenteric and renal arteries should be avoided<sup>[223]</sup>. Balloon expandable Palmaz stents are recommended for precise deployment just cephalad to a critical branch artery (superior mesenteric artery or renal artery)<sup>[223]</sup>; 14 mm diameter Wallstents<sup>[223,234,236]</sup> are an alternative.

Based on the measurements obtained during angiography, IVUS, TEE, CT or MRI, the individual graft stents are produced with a diameter of 2–4 cm covering 3–5 cm proximal and distal to the tear. Average stent grafts are 3.5 cm (2.4–4.5 cm) in diameter and 10.5 cm (4.5–22.5 cm) long. The right femoral artery is the common site for surgical insertion of the 22–27F systems, leaving the left side for percutaneous access to the aorta for angiography and IVUS. A stiff wire is placed after a pigtail catheter has been introduced over a soft wire.

The procedure is performed with the patient under general anaesthesia. Blood pressure is lowered to 50–60 mmHg by sodium nitroprusside during stent expansion. Upon stent expansion the aortic pressure would increase instantaneously because antegrade flow is blocked and will become free after complete stent graft delivery. After deployment of a stent, a balloon, incorporated in the system, allows further apposition of the stent struts to the wall of the true lumen. It is not the aim to perform wall wrapping of the intimal flap to the wall of the false lumen, but to occlude intimal tears.

#### *Branch vessel stenting*

A dissection that propagates into a branch artery and causes static obstruction is treated by direct branch vessel stents. A stent is indicated when a significant gradient between the branch artery and the supplying aortic lumen exists. It is important that the aortic true luminal cross section and true lumen pressures are reassessed after flow restoration in large arteries, as stenting of arterial branch stenoses can result in



significant reorientation of the dissection flap with the changed pressures in the supplying aortic lumen. Precise stent placement is crucial for these branch vessel obstructions. Stents with no or only minimal shortening (or balloon expandable stents, respectively) seem advantageous for branch vessel stenting. Consequently the Palmaz balloon expandable stent was used in all three major series published<sup>[224,234,236]</sup>.

### Results of interventional therapy

In 57 patients, flow could be restored in more than 90% (range 92 to 100%) of vessels obstructed from aortic dissection<sup>[223,224,234,235]</sup>. The average 30 day mortality rate was 10% (range 0 to 25%). No additional surgical revascularization was needed in any of the patients treated. Most of the patients remained asymptomatic over a mean follow-up time of about one year. All mortalities were unrelated to the percutaneous procedure and were usually the result of non-reversible ischaemic changes, progression of the dissection or complications of additional reconstructive surgical procedures on the thoracic aorta. Two patients died after 3 and 17 months, respectively, from rupture of the chronically enlarging false lumen<sup>[223]</sup>. Potential problems arise from unpredictable haemodynamic alterations in the true and false lumen after fenestration and stenting. These alterations may result in loss of previously well perfused arteries, as well as in loss of the desired salvage of compromised arteries. Affected arteries can also be managed by endovascular techniques such as additional stent procedures<sup>[223,224,234,236]</sup>.

First preliminary results of aortic graft stent implantation are currently becoming available<sup>[227,228]</sup>. It is already evident that percutaneous application is safer and produces better results than surgical graft stent implantation<sup>[228]</sup>. Paraplegia seems to occur, too, related to extensive graft stenting but not with short (<15 cm) stents and in consecutive instead of single approaches if longer segments have to be stented. Results on short-term follow-up were good, the tears became well occluded and aortic diameters decreased after complete thrombosis of the false lumen. This proves that stent placement may facilitate healing of the dissection. Whether or not additional tears in the abdominal part of the aorta have to be occluded when entry tears in the thoracic aorta are closed has to be demonstrated in the future. Endovascular leakages were found, occasionally with spontaneous occlusion of some portion of the leak and reopening of another during follow-up. In some patients follow-up showed that tears had initially been overlooked, and additional stents were implanted.

Patients can develop an inflammatory reaction after implantation. This may present as an elevated C-reactive protein in combination with fever. Both signs may disappear spontaneously as the healing progresses<sup>[236,237]</sup>.

### Complications of interventional therapy

In view of the fact that the post-procedural mortality rate seems largely dependent on the severity and duration of ischaemia before the interventional procedures — half of the 30 day mortalities (13%) were due to irreversible damage sustained before the endovascular treatment — timely percutaneous treatment seems mandatory<sup>[223]</sup>. It is therefore advocated that patients with acute type A dissection and malperfusion of peripheral branches should undergo percutaneous revascularization first, and surgical repair should be delayed until the ischaemic injury resolves<sup>[239]</sup>.

#### Summary

Interventional therapy in aortic dissection provides new approaches to handle complications.

Aortic fenestration with or without stent placement allows immediate relief of organ malperfusion for

- visceral
- renal
- limb ischaemia either before or after surgical treatment

Graft stent implantation is an evolving technique which opens new avenues to treat type B (type III) dissection. Occlusion of entry tears induces thrombus formation and vessel wall healing.

### Follow-up in aortic dissection

#### Natural history of aortic dissection and prognosis

Aortic dissection has a prevalence of 0.5 to 2.95/100 000/yr<sup>[240–242]</sup> with the highest rate in Italy (4.04/100 000/yr)<sup>[235]</sup>. Mortality is between 3.25–3.6/100 000/yr<sup>[244]</sup>.

Due to the high mortality of aortic dissection in the acute stage, the survival rate in both type A and B (type I–III) dissection is very low. Forty years ago, the 24 h mortality was 21%. After 30 days 8% of patients remained alive and only 2% after 1 year<sup>[97]</sup>. Ten years later the 48 h mortality was still reported to be 50% or 1%/h<sup>[240]</sup>. Up to 20% of the patients died before reaching the hospital. Even recently a mortality of 68% within 48 h and 1.4%/h was reported in a survey spanning 27 years<sup>[245]</sup>. In this population-based longitudinal study with an incidence of 2.95/100 000/yr the important observation was that the diagnosis was established in only 15% before autopsy. The most important causes of death were aortic rupture in 80% of the patients<sup>[245]</sup>.

A dramatic improvement can be observed, due to medical and surgical therapy over the last 30 years. The European Cooperative study group reported a 1 year survival rate of 52%, 69% and 70% in type A (type I, type II) and type B (type III) dissection, respectively. This decreased to 48%, 50% and 60% after 2 years<sup>[6]</sup>.

**Table 18 Prevention of aortic dissection in inherited diseases (Marfan's Syndrome, Ehlers-Danlos Syndrome, annuloaortic ectasia)**

Recommendation	Class I	IIa	IIb	Level of evidence
1. Life-long beta-adrenergic blockade	•			C
2. Periodic routine imaging of the aorta	•			C
3. Prophylactic replacement of the aortic root before diameter exceeds 5.0 cm in patients with family history of dissection		•		C
4. Prophylactic replacement of the aortic root before diameter exceeds 5.5 cm		•		C
5. Moderate restriction of physical activity	•			C

Similar results were reported by others, also showing a better prognosis for type B dissection. The 1 year survival was 34% and 85%, respectively<sup>[246,247]</sup>. The survival seems to be dependent on the degree of communication, that means the wall stress in the false lumen. The best prognosis was found in non-communicating and retrograde type B (type III) dissection limited to the descending aorta (80 and 86%, 2 year survival rate respectively)<sup>[6]</sup>.

Further improvement has not been reported during the last 20 years. The IRAD study reported a mortality of 27% and 29% for type A and B (type I–III) dissection in 464 patients after surgical therapy and 53% and 9% after medical therapy, respectively<sup>[248]</sup>.

Spontaneous healing of aortic dissection can occur during medical therapy, but it is rare. The false lumen disappears and circumscript wall thickening develops<sup>[6,94,111,112,249]</sup>. In the European Cooperative study wall thickening was observed as a sign of healing in only 4% of patients, mainly in type A (type II) and type B (type III) dissection<sup>[6]</sup>. In MRI studies this was observed in 7%<sup>[250]</sup>, by CT in 31% of type B (type III) dissections<sup>[251]</sup>. Continuous flow through large entry tears seems to prevent spontaneous healing<sup>[6]</sup>.

Another form of healing process is complete thrombosis of the false lumen which is sometimes observed and appears to be a prerequisite for complete healing<sup>[6,94,252]</sup>. The extent of thrombus formation is also important. This may be related to the fact that patients are already in a more chronic stage and the lack of communication and an increased wall thickness decrease wall stress. In 2% of patients a type B (type III) dissection with communication can continue to dissect into the ascending aorta in a retrograde fashion<sup>[94]</sup>. If the aortic arch is involved, the mortality is higher than with a type B (type III) dissection limited to the descending aorta<sup>[6]</sup>.

Present surgical techniques do not result in progression of thrombus formation in patients with aortic dissection: replacement of the ascending aorta alone cannot eliminate flow in the false lumen and thrombus formation is therefore not likely. Less than 10% of operated patients with type I dissection show an obliteration of the false lumen<sup>[6,250–255]</sup>.

Currently information about the natural history of intramural haematoma (class 2) is limited. The mortality is high: 20–80%<sup>[12,94,101,256]</sup>. The development of aortic

dissection class 1 is found in 15–41%<sup>[92,94,256–263]</sup>, rupture in 5–26%<sup>[12,259,263]</sup>. Complete healing on the other hand is found in 11–75% with resolution of the wall thickening<sup>[94,257,259,261,263,264]</sup>.

During follow-up, ulcerated plaques (class 4) seem to be more malignant with class 1 dissection of the descending aorta: there are more aortic ruptures. Others reported a more benign course and did not consider immediate surgery<sup>[106,108]</sup>. However, subintimal haematoma and complicated ulcers represent signs of emergency with pending rupture. Ulcerated plaques can form large pseudoaneurysms<sup>[265–267]</sup>. Development of class 1 dissection is found in 10–20%. Traumatic aortic dissection (class 5) has also a poor prognosis, but limited data are available<sup>[268–272]</sup>.

### Follow-up in Marfan patients

The accepted critical aortic root dimension of 5.0–5.5 cm may be seen at any age, even in infancy, and suggests that intervention is advisable in anticipation of subsequent dissection, as for the fully grown population (Table 18). The general agreement is, that prophylactic replacement of the aortic root should be performed at a diameter of 5.5 cm in Marfan patients<sup>[273–278]</sup>. A smaller threshold may apply in the very young but the difficulty in defining an absolute upper dimension in childhood is that growth must be accounted for. The particular growth upper dimension in childhood is that growth must be taken into account. The particular growth pattern of the Marfan phenotype needs to be considered as well. Aortic root dimensions (Fig. 2) should be plotted serially (not against age, but against body surface area) at least annually, possibly more frequently in very young children, and certainly during the rapid adolescent growth spurt. The dimensions assessed by echocardiography may well lie outside the upper confidence interval (Fig. 3) for the normal population, but may follow a centile above but parallel to it. Should the dimensions deviate (upward) from the pursued centile, then it is the time to consider intervention<sup>[279,280]</sup>.

It is imperative that further longitudinal studies are undertaken to define the normal aortic root growth pattern in Marfan's syndrome from very early childhood. Guidelines for clinical decision should be derived from such data to decide the minimal deviation from the

**Table 19 Reoperation following repair of aortic dissection**

Recommendation	Class I	IIa	IIb	Level of evidence
1. Surgical intervention for				
• secondary aneurysm in dissected aorta remote from initial repair	•			C
• recurrent dissection or aneurysm formation at previous intervention site	•			C
2. Graft replacement for gross dehiscence or infection	•			C
3. Use of homografts to replace infected prostheses		•		C
4. Endovascular stenting <i>if</i> surgical indication and suitable anatomy		•		C

norm, with respect to the risk of dissection; but can be accepted.

Consideration should also be given to include replacement of an ectatic aortic root (Table 16), even if it has not reached the accepted dimension for replacement, if another cardiac operative procedure is to be undertaken.

There are no guidelines governing intervention in cases of aneurysmal dilatation of other segments of the aorta as a prophylactic measure against dissection. It might be prudent to take action if a sudden or rapid expansion is recognized<sup>[279,280]</sup>.

There is little evidence that exercise in childhood, or any particular type of activity influences the rate of progression of aortic root dilatation, though there is a report of a teenager in whom dissection was precipitated by (recreational) weight lifting<sup>[281]</sup>. Advice (Table 19) concerning exercise is considered important. Blood pressure should not exceed 130 mmHg systolic; this holds true for children and adults<sup>[281]</sup>.

### *Imaging for follow-up studies*

Patients with aortic dissection need close follow-up. The main task is to control blood pressure in order to reduce wall stress. A level below 135/80 mmHg is advised. This is the same level as for patients without aortic dissection but arterial hypertension. Beta-blocking agents are preferred. Combination therapy with other drugs is usually needed to control the pressure. The recommendation concerning blood pressure control should be followed. Specialized physicians with a deep insight into the patients' history and knowledge of aortic dissection including different treatment options should follow the patients in order to detect signs of progression of the disease or aneurysm formation.

To follow patients after medically or surgically treated acute aortic dissection, MRI appears to be the technique of choice (Table 13). MRI avoids exposure to ionizing radiation or nephrotoxic contrast agents used for CT and is less invasive than transoesophageal echocardiography. An important consideration in serial studies is the ease with which serial findings can be compared<sup>[282,283]</sup>. Documentation of MR-studies on a series of prints rather than video tape facilitates the diagnosis of progressive enlargement of the false lumen or the entire aorta. Moreover, the large field of view permits visualization of neighbouring anatomical landmarks in order

to make measurements at identical levels of the aorta. In patients after surgical repair of the dissection, knowledge of the surgical technique performed is essential for correct interpretation of all imaging techniques including MRI. The second choice represents TEE, but careful documentation of the scan fields is necessary when the question concerning aortic expansion has to be answered. CT can also be used and it is the technique which is most frequently performed. In the age after 60 years the negative effect of ionizing X-ray exposure can be neglected compared to the severity of the disease.

Regular assessment of the aorta should be performed 1, 3, 6 and 12 months after the acute event, followed by yearly examinations. Most important are the aortic diameter, signs of aneurysm formation; haemorrhages at surgical anastomoses or graft stent sites have to be detected.

#### *Summary*

Close follow-up for aortic dissection by a specialized team includes the assessment of

- signs of aortic expansion
- aneurysm formation
- signs of leakages at anastomoses/stent sites
- malperfusion

The single most important factor is excellent blood pressure control <135/80 mmHg. After hospital discharge regular outpatient visits at 1, 3, 6 and 12 month and thereafter every year are recommended. First choice is MRI, 2nd choice CT and 3rd TEE.

### *Reoperation*

The majority of late deaths following primary surgery of acute aortic dissection has been due to rupture of the aorta<sup>[88]</sup>. Therefore, timely reoperation (Table 19) is required whenever necessary. There are two principal reasons for reoperation. First, the dissected aorta may become aneurysmatic (5 to 6 cm in diameter) remote from the initial repair (Table 20). The second reason derives from instances where the dissection had been improperly repaired. The rate of reoperation for type I and type II dissection is about 10% at 5 years and up to 40% at 10 years after primary surgery<sup>[6,246]</sup>. This risk is even higher in patients with Marfan's syndrome<sup>[277,278]</sup>.

Table 20 Therapy of chronic aortic dissection

Recommendation	Class I	IIa	IIb	Level of evidence
Type A (type I, II):				
1. Indications for surgery as in non-dissecting aneurysm <i>if</i> symptoms or aortic regurgitation or aortic diameter >(5-) 6 cm	•			C
Type B (type III):				
1. Indications for surgery as in non-dissecting aneurysms <i>if</i> symptoms or progressive aortic enlargement to $\geq 6.0$ cm	•			C
2. Endovascular stenting <i>if</i> surgical indication and suitable anatomy		•		C

The proximal aorta, particularly the aortic root and ascending portion is the most common site requiring reoperation. The underlying causes are generally iatrogenic: the dissection may either have persisted after the primary procedure or may have recurred later. The incidence of new dissection including the ascending aorta varies from 0.03 to 0.1%<sup>[284–286]</sup>. After aortic valve replacement, it occurs in 0.5%–1%<sup>[76,287–288]</sup>. Some conditions that predispose to subsequent dissection include previous aortic valve replacement, congenitally deformed valves or overlooked annuloaortic ectasia<sup>[289,290]</sup>. Others cases include root aneurysms, redissection after glue repair or composite replacement<sup>[291,292]</sup>.

The key to a successful reoperation on the dissected proximal aorta is safe entry into the chest, while all subsequent manoeuvres tend to follow the principles of standard surgery in this region. Great care must be exercised when performing repeat sternotomy because the aorta is usually unprotected by the pericardium. This is particularly true in cases where an ascending aortic tube graft or an aneurysm is closely adherent to the posterior table of the sternum in association with severe aortic valve incompetence. The approach to these combined lesions may require deviation from the routine longitudinal sternotomy in order to avoid both fatal bleeding and left ventricular overdistension. In such instances, a fifth-rib bilateral or unilateral thoracotomy with transverse sternotomy and prior institution of right atrial-femoral or femoro-femoral bypass are recommended<sup>[293]</sup>.

A modification of this approach has been reported for ascending aortic reoperations in the presence of aortic valve incompetence: instead of completing the re-sternotomy at moderate hypothermia a limited, inferior re-sternotomy is performed first<sup>[294]</sup>. Then, dissection of the diaphragmatic aspect of both the left and right ventricle allows the introduction of an apical vent. With the vent in place, core cooling is continued until the onset of ventricular fibrillation. If inadequate perfusion pressure prevents sufficient lowering of the temperature, the aorta may be occluded by apical insertion and inflation of a balloon catheter in the ascending aorta when clamping of the aorta is impossible because of tissue stiffness tissue or difficult exposure<sup>[295]</sup>. At a rectal temperature of 25 °C, circulatory arrest is induced. Under this condition, the heart and the ascending aorta

tend to collapse which makes dissection of retrosternal adhesions and completion of re-sternotomy much easier and safer. Cardiopulmonary bypass is reinstated once the ascending aorta is dissected free and clamped. Then, the core temperature may either be lowered to 20 °C before re-induction of circulatory arrest whenever the correction of aortic arch pathology is necessary or hypothermia may be maintained during the repair of the ascending aorta.

The choice of procedure depends on the state of the root. In the absence of root ectasia, the dissected wall layers may simply be conjoined and anastomosed to an ascending aortic tube graft. Depending on the coronary ostia vis-a-vis the valve's suturing ring they may be anastomosed directly to the graft or after mobilizing ostial buttons.

When performing surgery for complications of a previously implanted composite graft, several alternatives may be used. Minor leaks (communications with the perigraft space) at the ostial anastomoses or at the valve's insertion line can sometimes be closed directly. In gross dehiscence of the aortic or coronary ostial anastomoses, particularly if associated with infection, the conduit is replaced, in the latter case an allograft conduit is preferred.

Coronary bypass grafts require particular attention when performed in conjunction with surgery on the proximal aorta. If a left internal mammary artery graft had been placed its pedicle is carefully dissected away from the distal anastomosis and its bulk is clamped. Right internal mammary artery grafts will often interfere with the aortic procedure and may have to be divided proximally; ultimately they are anastomosed to the ascending aortic prosthesis.

Late complications following primary operations on the aortic arch are encountered less frequently than those following root and the ascending aortic procedures<sup>[267]</sup>. Aneurysmal dilatation of the false channel of the arch can usually be traced to the arch entries not being resected or to creation of new tears when the distal graft to aortic anastomosis was constructed during the primary procedure<sup>[296,297]</sup>. In these instances reoperative replacement of that structure may be required. The proximal repair is often left intact. The procedure follows the principles of primary arch replacement: a separate graft is used which is ultimately anastomosed to



the proximal prosthesis following resection of the true aortic channel.

### Appendix 1: ESC Task Force on Aortic Dissection

Raimund Erbel, MD, FESC, FACC, Department of Cardiology, Essen University, Germany

Fernando Alfonso, MD, FESC, Interventional Cardiology Unit, Hospital Universitario San Carlos, Madrid, Spain

Catherine Boileau, Hopital Necker — Enfants Malades, Clinique Maurice Lamy, France

Olaf Dirsch, MD, Department of Pathology, University Essen, Germany

Bernd Eber, MD, FESC, Department of Internal Medicine, Hospital of Barmherzige Schwestern, Wels, Austria

Axel Haverich, MD, Division of Thoracic and Cardiovascular Surgery, Hannover Medical School, Germany (representative of European Society of Cardiac Surgery)

Kjell Rådegran, MD, Department of Thoracic Surgery, Karolinska Hospital, Stockholm, Sweden (representative of European Society of Cardiac Surgery)

Harry Rakowski, MD, FACC, Toronto, Canada (representative of the American College of Cardiology, president American Society of Echocardiography)

Udo Sechtem, MD, FESC, Department of Cardiology and Pulmonology, Robert-Bosch-Krankenhaus, Stuttgart, Germany

Julien Struyven, MD, Department of Radiology, Hopital Erasme Université Bruxelles, Belgium (representative of Cardiovascular and Interventional Radiological Society (CIRSE))

James F. N. Taylor, Great Ormond Street Hospital for Children NHS Trust and the Institute of Child Health, London, United Kingdom (representative of European Society of Paediatric Cardiology)

Christoph L. Zollikofer, MD, Institute of Radiology, Kantonsspital Winterthur, Schweiz (representative of European Association of Radiology)

### Appendix 2: ESC Board and SCI Committee Reviewers

Maarten Simoons, MD, FESC (President), FACC, Thoraxcenter, University Hospital Rotterdam, Netherlands  
Lars Ryden, MD, FESC (Past President), FACC, Department of Cardiology, Karolinska Hospital, Stockholm, Sweden

Jean Pierre Bassand, MD, FESC (President elect), FACC, Department of Cardiology, Pole Coeur Poumon, Univ. Hosp., Jean-Minjoz, Besançon, France  
Werner Klein, MD, FESC (Chairman SCI Committee), FACC, Department of Cardiology, University Graz, Austria

Barbara Mulder, MD, Academic Medical Centre, Amsterdam, Netherlands

Adam Torbicki, MD, FESC, Department of Chest Medicine, Institute of Tuberculosis and Lung Disease, Warszawa, Poland

Luis A. Providencia, MD, FESC, Department of Cardiology, Coimbra University, Portugal

### Appendix 3: ACC Board of Trustees

George Beller, MD, FACC, Department of Internal Medicine, University of Virginia, Charlottesville, U.S.A.  
Morton F. Arnsdorf, MD, FACC, Department of Medicine, Cardiology, University of Chicago, Chicago, U.S.A.

Marian C. Limacher, MD, FACC, Division of Cardiovascular Medicine, University of Florida, Gainesville, U.S.A.

Phyllis M. Tahmasebi, Senior Administrative Coordinator, ACC

### Appendix 4: Evidence-based decision in tabular form

In comparison to medical therapy, limited data are available for diagnostic techniques which are required in evidence-based medicine for categories A and B. Therefore category C had to be chosen and subclassification in relation to the degree of consensus according to the ACC/AHA Guideline Classification for Recommendation.

Class I	Conditions for which there is evidence or general agreement that a given procedure or treatment is useful and effective
Class II	Conditions for which there is conflicting evidence or a divergence of opinion about the usefulness/efficacy of a procedure or treatment
Class IIa	weight of evidence /opinion is in favour of usefulness/efficacy
Class IIb	usefulness/efficacy is less well established by evidence/opinion
Class III	Conditions for which there is evidence and/or general agreement that the procedure/treatment is not useful/effective and in some cases may be harmful

#### *Financial support*

The Task Force wishes to express its appreciation for the financial support provided by the Board of the European Society of Cardiology.

The authors thank Dr Zeidan for his help in preparing the manuscript, Mrs Celesnik and Mrs Gerstberger for their intense secretarial work and Dr Splittgerber for reviewing the English manuscript.

### References

- [1] Sans S, Kesteloot H, Kromhout D on behalf of the Task Force. Task Force of the European Society of Cardiology on

- cardiovascular mortality and morbidity statistics. *Europe. Eur Heart J* 1997; 18: 1231–48.
- [2] Godwin JD. Conventional CT of the aorta. *J Thorac Imaging* 1990; 5: 18–31.
- [3] Erbel R, Engberding R, Daniel W, Roelandt J, Visser CM, Rennollet H. Echocardiography in diagnosis of aortic dissection. *Lancet* 1989; 1: 457–61.
- [4] Posniak HV, Olson MC, Demos TC, Benjoya RA, Marsan RE. CT of thoracic aortic aneurysms. *Radiographics* 1990; 10: 839–55.
- [5] Nienaber CA, Spielmann RP, von Kodolitsch Y *et al.* Diagnosis of thoracic aortic dissection. Magnetic resonance imaging versus transesophageal echocardiography. *Circulation* 1992; 85: 434–47.
- [6] Erbel R, Oelert H, Meyer J *et al.* Influence of medical and surgical therapy on aortic dissection evaluated by transesophageal echocardiography. *Circulation* 1993; 87: 1604–15.
- [7] Beighton P, de Paepe A, Danks D, and 17 co-authors. International nosology of heritable disorders of connective tissue. Berlin 1986. *Am J Med Genet* 1988; 29: 581–94.
- [8] De Paepe A, Devereux R, Dietz H, Hennekam R, Pyeritz R. Revised diagnostic criteria for the Marfan syndrome. *Am J Med Genet* 1996; 62: 417–26.
- [9] Sakai L, Keene D, Engvall E. Fibrillin, a new 350 kD glycoprotein is a compound of extracellular microfibrils. *J Cell Biol* 1986; 103: 2499–509.
- [10] Collod G, Babron MC, Jondeau G *et al.* A second locus for Marfan syndrome maps to chromosome 3p24.2-p25. *Nat Genet* 1994; 8: 264–8.
- [11] Sood S, Eldadah Z, Krause W, McIntosh I, Dietz H. Mutation in fibrillin-1 and the Marfanoid-craniosynostosis (Shprintzen-Goldberg) syndrome. *Nat Genet* 1996; 12: 209–11.
- [12] Milewicz DM, Michael K, Fisher N, Coselli J, Markello T, Biddinger A. Fibrillin-1 (FBN1) mutations in patients with thoracic aortic aneurysms. *Circulation* 1996; 94: 2708–11.
- [13] Glesby M, Pyeritz R. Association of mitral valve prolapse and systemic abnormalities of connective tissue. A phenotypic continuum. *JAMA* 1989; 262: 523–8.
- [14] Ramirez F. Fibrillin mutations in Marfan syndrome and related phenotypes. *Curr Opin Genet Dev* 1996; 6: 309–15.
- [15] Boileau C, Jondeau G, Babron MC *et al.* Autosomal dominant Marfan-like connective-tissue disorder with aortic dilatation and skeletal anomalies not linked to the fibrillin genes. *Am J Hum Genet* 1993; 53: 46–54.
- [16] Milewicz DM, Pyeritz RE, Crawford ES, Byers PH. Marfan syndrome: defective synthesis, secretion and extracellular matrix formation of fibrillin by cultured dermal fibroblasts. *J Clin Invest* 1992; 89: 79–86.
- [17] Aoyama T, Francke U, Dietz H, Furthmayer H. Quantitative differences in biosynthesis and extracellular deposition of fibrillin in cultured fibroblasts distinguish five groups of Marfan syndrome patients and suggest distinct pathogenetic mechanisms. *J Clin Invest* 1994; 94: 130–7.
- [18] Beighton P. 'The Ehlers-Danlos syndrome'. London: William Heinemann Medical Books, 1970.
- [19] Steinmann B, Royce P, Superti-Furga A. The Ehlers-Danlos syndrome. In: Royce PM, Steinmann B, eds. *Connective Tissue and its heritable disorders*. New York: Wiley-Liss Inc., 1993; 351–407.
- [20] Biddinger A, Rocklin M, Coselli J, Milewicz DM. Familial thoracic aortic dilatations and dissections: a case control study. *J Vasc Surg* 1997; 25: 506–11.
- [21] Dalgleish R. The human collagen mutation database 1998. *Nucleic Acids Res* 1998; 26: 253–5.
- [22] Collagen database: <http://www.Le.ac.uk/genetics/collagen>.
- [23] Ellis PR, Cooley DA, De Bakey ME. Clinical consideration and surgical treatment of annuloaortic ectasia. *J Thorac Cardiovasc Surg* 1961; 42: 363–70.
- [24] Coady M, Davies R, Roberts M *et al.* Familial patterns of thoracic aortic aneurysms. *Arch Surg* 1999; 134: 361–7.
- [25] Furthmayer H, Francke U. Ascending aortic aneurysm with or without features of Marfan syndrome and other fibrillinopathies: new insights. *Semin Thorac Cardiovasc Surg* 1997; 9: 191–205.
- [26] Kantonen I, Savunen T, Peltonen L. Linkage analysis in Finnish families with annulo-aortic ectasia. Davos, 1996.
- [27] Muluk S, Gertler J, Brewster D *et al.* Presentation and patterns of aortic aneurysms in young patients. *J Vasc Surg* 1994; 20: 880–8.
- [28] OMIM (On line Mendelian Inheritance in Man). <http://www.ncbi.nlm.nih.gov/Omim/>.
- [29] Darling R, Brewster D, Darling R *et al.* Are familial abdominal aortic aneurysms different? *J Vasc Surg* 1989; 10: 39–43.
- [30] Majumder PP, St. Jean PL, Ferrell RE, Webster MW, Steed DL. On the inheritance of abdominal aortic aneurysm. *Am J Hum Genet* 1991; 48: 164–70.
- [31] Verloes A, Sakalihasan N, Koulischer L, Limet R. Aneurysms of the abdominal aorta: familial and genetic aspects in three hundred thirteen pedigrees. *J Vasc Surg* 1995; 21: 646–55.
- [32] Pope FM, Narcisi P, Nicholls AC, Germaine D, Pals G, Richards AJ. COL3A1 mutations cause variable clinical phenotypes including acrogeria and vascular rupture. *Br J Dermatol* 1996; 135: 163–81.
- [33] Roman MJ, Devereux RB, Kramer-Fox R, O'Loughlin J. Two-dimensional echocardiographic aortic root dimensions in normal children and adults. *Am J Cardiol* 1989; 64: 507–12.
- [34] Ruiz ME, Sty JR, Wells RG. Aortic dissection in a 5-year old girl with Marfan's syndrome. *Arch Pediatr Adolesc Med* 1996; 150: 440–2.
- [35] Agarwala BN. Group B streptococcal endocarditis in a neonate. *Pediatr Cardiol* 1988; 9: 51–3.
- [36] Sakurai M, Maeda M, Sai N, Miyahara M, Nakayama M, Takemura H. Aortic dissection in an infant caused by intraaortic balloon pumping. *Pediatr Cardiol* 1999 (in press).
- [37] Vitiello R, McCrindle BW, Nykanen D, Freedom RM, Benson LN. Complications associated with pediatric cardiac catheterization. *J Am Coll Cardiol* 1998; 32: 1433–40.
- [38] Crawford ES, Coselli JS, Safi HJ. Reoperations for thoracic and thoracoabdominal aneurysms. In: Stark J, Pacifico AD, eds. *Reoperations in cardiac surgery*. Springer Verlag, 1989: 361–81.
- [39] Svensson LG, Crawford ES, Coselli JS, Safi HJ, Hess KR. Impact of cardiovascular operation on survival in the Marfan patients. *Circulation* 1989; 80: 1 233–42.
- [40] Gillinov AM, Zehr KJ, Redmond JM, Gott VL, Deitz HC, Reitz BA, Laschinger JC, Cameron DE. Cardiac operations in children with Marfan's syndrome: indications and results. *Ann Thorac Surg* 1997; 64: 1140–4; discussion 1144–5.
- [41] Cavanzo F, Taylor HB. Effect of pregnancy on the human aorta and its relationship to dissecting aneurysms. *Am J Obstet Gynecol* 1969; 105: 567–8.
- [42] Burks JM, Illes RW, Keating EC, Lubbe WJ. Ascending aortic aneurysm and dissection in young adults with bicuspid aortic valve: implications for echocardiographic surveillance. *Clin Cardiol* 1998; 21: 439–43.
- [43] Harker LA, Slichter SJ, Scott CR, Ross R. Homocystinuria. Vascular injury and arterial thrombosis. *N Engl J Med* 1974; 291: 537–43.
- [44] Millar AJ, Gilbert RD, Brown RA, Immelman EJ, Barkinsher DA, Cywes S. Abdominal aortic aneurysms in children. *J Pediatr Surg* 1996; 31: 1624–8.
- [45] Drexler M, Erbel R, Müller U, Wittlich N, Mohr-Kahaly S, Meyer J. Measurement of intracardiac dimensions and structures in normal young adult subjects by transesophageal echocardiography. *Am J Cardiol* 1990; 65: 1491–6.
- [46] Brown OR, DeMots H, Kloster FE, Roberts A, Menashe VD, Beals RK. Aortic root dilatation and mitral valve prolapse in Marfan's syndrome: an echocardiographic study. *Circulation* 1975; 52: 651–7.

- [47] Stein HL, Steinberg I. Selective aortography, the definitive technique for diagnosis of dissecting aneurysm of the aorta. *Am J Roentgenol Radium Ther Nucl Med* 1968; 102: 333–48.
- [48] Hayashi K, Meaney TF, Zelch JV, Tarar R. Aortographic analysis of aortic dissection. *Am J Roentgenol Radium Ther Nucl Med* 1974; 122: 769–82.
- [49] Mohr-Kahaly S, Erbel R. Advantages of biplane and multiplane transesophageal echocardiography for the morphology of the aorta. *Am J Card Imaging* 1995; 9: 115–20.
- [50] Taylor KM. Diseases of the aorta. In: Julian DG, Camm AJ, Fox KM, Hall RJC, Poole-Wilson PA, eds. *Diseases of the Heart*, 1st edn. London: Bailliere Tindall, 1989: 1338–62.
- [51] Roberts WC. Aortic dissection: anatomy, consequences and causes. *Am Heart J* 1981; 101: 195–214.
- [52] Nevitt MP, Ballard DJ, Hallet JW. Prognosis of abdominal aortic aneurysms. A population-based study. *N Engl J Med* 1989; 321: 1009–14.
- [53] McNamara JJ, Pressler V. Natural history of atherosclerotic thoracic aortic aneurysms. *Ann Thorac Surg* 1978; 26: 468–73.
- [54] Masuda Y, Takanashi K, Takasu J, Morooka N, Inagaki Y. Expansion rate of thoracic aortic aneurysms and influencing factors. *Chest* 1992; 102: 461–6.
- [55] Süttsch G, Jenni R, von Segesser L, Turina M. Predictability of aortic dissection as a function of aortic diameter. *Eur Heart J* 1991; 12: 1247–56.
- [56] Gott VL, Pyeritz RE, Magovern GJ, Cameron DE, McKusick VA. Surgical treatment of aneurysms of the ascending aorta in the Marfan syndrome. *N Engl J Med* 1986; 314: 1070–4.
- [57] Bruno L, Prandi M, Colombi P, La Vecchia L. Diagnostic and surgical management of patients with aneurysms of the thoracic aorta with various causes. *Br Heart J* 1986; 55: 81–91.
- [58] Miller DC. Surgical management of aortic dissections: indications, perioperative management, and long-term results. In: Doroghazi RM, Slater EE, eds. *Aortic dissection*. New York: McGraw-Hill, 1983: 193–243.
- [59] Louridas G, Reilly K, Perry MO. The role of the aortic aneurysm diameter to aortic diameter ratio in predicting the risk of rupture. *S Afr Med J* 1990; 78: 642–3.
- [60] Lemon DK, White CW. Annuloaortic ectasia: angiographic, hemodynamic and clinical comparison with aortic valve insufficiency. *Am J Cardiol* 1978; 41: 482–6.
- [61] McDonald GR, Schaff HV, Pyeritz RE, McKusick VA, Gott VL. Surgical management of patients with the Marfan syndrome and dilatation of the ascending aorta (authors transl). *J Thorac Cardiovasc Surg* 1981; 81: 180–6.
- [62] White RD, Lipton MJ, Higgins CB *et al.* Noninvasive evaluation of suspected thoracic aortic disease by contrast-enhanced computed tomography. *Am J Cardiol* 1986; 57: 282–90.
- [63] Tjon-A-Meeuw L, Bollinger A. [Aneurysm of the abdominal aorta. Diagnosis and indications for therapy]. *Schweiz Med Wochenschr* 1991; 121: 683–92.
- [64] Stefanadis CI, Karayannacos PE, Boudoulas HK *et al.* Medial necrosis and acute alterations in aortic distensibility following removal of the vasa vasorum of canine ascending aorta. *Cardiovasc Res* 1993; 27: 951–6.
- [65] Mohr-Kahaly S, Erbel R, Stähn P, Hake U, Oelert H, Meyer J. [Quantitative detection of changes in the thoracic aorta in patients with chronic aortic dissection using transesophageal echocardiography]. *Z Kardiol* 1999; 88: 507–13.
- [66] Kunz R. [Aneurysms in 35,380 autopsies]. *Schweiz Med Wschr* 1980; 110: 142–8.
- [67] Young R, Osterreich H. [Incidence etiology and risk of rupture of aortic aneurysm. An autopsy study]. *Dtsch Med Wschr* 1987; 112: 1253–6.
- [68] Reed D, Reed C, Stemmermann G, Hayashi T. Are aortic aneurysms caused by atherosclerosis? *Circulation* 1992; 85: 205–11.
- [69] Parmley LF, Mattingly TW, Manion WC, Jahuke EJ. Non-penetrating traumatic injury of the aorta. *Circulation* 1958; 17: 1086–101.
- [70] Von Oppell UO, Thierfelder CF, Beningfield SJ, Brink JG, Odell JA. Traumatic rupture of the descending thoracic aorta. *S Afr Med J* 1991; 79: 595–8.
- [71] Ammons MA, Moore EE, Moore FA, Hopeman AR. Intra-aortic balloon pump for combined myocardial contusion and thoracic aortic rupture. *J Trauma* 1990; 30: 1606–8.
- [72] Dorsa FB, Tunick PA, Culliford A, Kronzon I. Pseudo-aneurysm of the thoracic aorta due to cardiopulmonary resuscitation: diagnosis by transesophageal echocardiography. *Am Heart J* 1992; 123: 1398–400.
- [73] Fredman C, Serota H, Deligonul U, Barner H, Pearson A, Kern MJ. Ascending aortic aneurysm masquerading as fever, altered mental status and mediastinal mass. *Am Heart J* 1990; 119: 408–10.
- [74] Patel KL, Gross J. Extracorporeal shock wave lithotripsy induced abdominal aortic aneurysm rupture. *J Am Geriatr Soc* 1991; 39: 318–9.
- [75] Moles VP, Chappuis F, Simonet F, Urban P, De La Serna F, Pande AK, Meier B. Aortic dissection as complication of percutaneous transluminal coronary angioplasty. *Cathet Cardiovasc Diagn* 1992; 26: 8–11.
- [76] Pieters FAA, Widdershoven JW, Gerardy AC, Geskes G, Cheriex EC, Wellens HJ. Risk of aortic dissection after aortic valve replacement. *Am J Cardiol* 1993; 72: 1043–7.
- [77] Epperlein S, Mohr-Kahaly S, Erbel R, Kearney P, Meyer J. Aorta and aortic valve morphologies predisposing to aortic dissection. An in vivo assessment with transesophageal echocardiography. *Eur Heart J* 1994; 15: 1520–7.
- [78] Leu HJ. Classification of vasculitides. A survey. *Vasa* 1995; 24: 319–24.
- [79] Churg A, Churg J. *Systemic vasculitides*, 1st edn. New York, Tokyo: Igaku-Shoin, 1991.
- [80] Webster B, Rich C, Densen PM, Moore JE, Nicol CS, Padgett P. Studies on cardiovascular syphilis. *Am Heart J* 1953; 46: 117–45.
- [81] Boussou H, Julian M, Pieraggi MT. Aortic lathyrism and atheroma in the rat by prolonged hyperlipidic diet. *Gerontology* 1978; 24: 250–65.
- [82] Boor PJ, Gotlieb AI, Joseph EC, Kerns WD, Roth RA, Tomaszewski KE. Chemical-induced vasculature injury. Summary of the symposium presented at the 32nd annual meeting of the Society of Toxicology, New Orleans, Louisiana, March 1993. *Toxicol Appl Pharmacol* 1995; 132: 177–95.
- [83] Dewar WA, Wight PA, Pearson RA, Gentle MJ. Toxic effects of high concentrations of zinc oxide in the diet of the chick and laying hen. *Br Poult Sci* 1983; 24: 397–404.
- [84] Arannis FW Jr, Bryant C, Caffaratti JD, Turner AF. Acute aortic dissection associated with cocaine abuse. *Clin Cardiol* 1988; 11: 572–4.
- [85] Rashid J, Eisenberg MJ, Topol EJ. Cocaine-induced aortic dissection. *Am Heart J* 1996; 132: 1301–4.
- [86] Crawford ES, Svensson LG, Coselli JS, Safi HJ, Hess KR. Surgical treatment of aneurysm and/or dissection of the ascending aorta, transverse aortic arch, and ascending aorta and transverse aortic arch. Factors influencing survival in 717 patients. *J Thorac Cardiovasc Surg* 1989; 98: 659–74; discussion 673–4.
- [87] De Bakey ME, McCollum CH, Crawford ES *et al.* Dissection and dissecting aneurysms of the aorta: twenty-year follow-up of five hundred and twenty-seven patients treated surgically. *Surgery* 1982; 92: 1118–34.
- [88] Reul GJ, Cooley DA, Hallman GL, Reddy SB, Kyger ER 3rd, Wukasch DC. Dissecting aneurysm of the descending aorta. *Arch Surg* 1975; 110: 632–40.
- [89] Svensson LG, Labib SB, Eisenhauer AC, Butterly JR. Intimal tear without hematoma. *Circulation* 1999; 99: 1331–6.
- [90] Yamada T, Tada S, Harada J. Aortic dissection without intimal rupture: diagnosis with MR imaging and CT. *Radiology* 1988; 168: 347–52.



- [91] Mohr-Kahaly S, Erbel R, Kearney P, Puth M, Meyer J. Aortic intramural hematoma visualized by transesophageal echocardiography: findings and prognostic implications. *J Am Coll Cardiol* 1994; 23: 658–64.
- [92] Nienaber CA, von Kodolitsch Y, Petersen B *et al.* Intramural hemorrhage of the thoracic aorta. Diagnostic and therapeutic implications. *Circulation* 1995; 92: 1465–72.
- [93] Roberts CS, Roberts WC. Aortic dissection with the entrance tear in the descending thoracic aorta. *Ann Surg* 1991; 213: 356–68.
- [94] Mohr-Kahaly S, Erbel R, Rennollet H *et al.* Ambulatory follow-up of aortic dissection by transesophageal two-dimensional and color-coded Doppler echocardiography. *Circulation* 1989; 80: 24–33.
- [95] Krükenberg E. Beiträge zur Frage des Aneurysma dissecans. *Allg Path* 1920; 67: 329–51.
- [96] Gore I. Pathogenesis of dissecting aneurysm of aorta. *Arch Path Lab Med* 1952; 53: 142–53.
- [97] Hirst AE Jr, Johns VJ Jr, Kime SW Jr. Dissecting aneurysm of the aorta: a review of 505 cases. *Medicine* 1958; 37: 217–79.
- [98] Klotz O, Simpson W. Spontaneous rupture of aorta. *Am J Med Sci* 1932; 184: 455–73.
- [99] Stellwag-Carion C, Pollak St. [Idiopathic aortic rupture as a cause of sudden death]. *Beitr Gerichtl Med* 1978; 36: 307–17.
- [100] Weintraub AR, Erbel R, Gorge G *et al.* Intravascular ultrasound imaging in acute aortic dissection. *J Am Coll Cardiol* 1994; 24: 495–503.
- [101] Alfonso F, Goicolea J, Aragoncillo P, Hernandez R, Macaya C. Diagnosis of aortic intramural hematoma by intravascular ultrasound imaging. *Am J Cardiol* 1995; 76: 735–8.
- [102] Zotz R, Erbel R, Meyer J. Noncommunicating intrawall hematoma as an early sign aortic dissection. *J Am Soc Echocardiogr* 1991; 4: 636–8.
- [103] O'Gara PT, DeSanctis RW. Acute aortic dissection and its variants. *Circulation* 1995; 92: 1376–8.
- [104] Shimizu H, Yohino H, Udagawa H *et al.* Prognosis of intramural hemorrhage compared with classic aortic dissection. *Am J Cardiol* 2000; 85: 792–5.
- [105] Stanson AV, Kazmier FJ, Hollier LH *et al.* Penetrating atherosclerotic ulcers of the thoracic aorta: natural history and clinicopathologic correlations. *Ann Vasc Surg* 1986; 1: 15–23.
- [106] Cooke JP, Kazmier FJ, Orszulak TA. The penetrating aortic ulcer: pathologic manifestations, diagnosis and management. *Mayo Clin Proc* 1988; 63: 718–25.
- [107] Yucel EK, Steinberg FL, Egglin TK, Geller SC, Waltman AC, Athanasoulis CA. Penetrating aortic ulcers: diagnosis with MR imaging. *Radiology* 1990; 177: 779–81.
- [108] Kazerooni EA, Bree RL, Williams DM. Penetrating atherosclerotic ulcers of the descending thoracic aorta: evaluation with CT and distinction from aortic dissection. *Radiology* 1992; 183: 759–65.
- [109] Braverman AC. Penetrating atherosclerotic ulcers of the aorta. *Curr Opin Cardiol* 1994; 9: 591–7.
- [110] Movsowitz HD, Lampert C, Jacobs LE, Kotler MN. Penetrating atherosclerotic aortic ulcers. *Am Heart J* 1994; 128: 1210–7.
- [111] Erbel R, Bednarczyk I, Pop T *et al.* Detection of dissection of the aortic intima and media after angioplasty of coarctation of the aorta. An angiographic, computer tomographic, and echocardiographic comparative study. *Circulation* 1990; 81: 805–14.
- [112] Alfonso F, Almeria C, Fernandez-Ortiz A *et al.* Aortic dissection occurring during coronary angioplasty: angiographic and transesophageal echocardiographic findings. *Cathet Cardiovasc Diagn* 1997; 42: 412–5.
- [113] Slater EE, DeSanctis RW. The clinical recognition of dissecting aortic aneurysm. *Am J Med* 1976; 60: 625–33.
- [114] Svensson LG, Crawford ES. Aortic dissection and aortic aneurysm surgery: clinical observations, experimental investigations and statistical analyses. Part II. *Curr Probl Surg* 1992; 29: 913–1057.
- [115] Hagan PG, Nienaber CA, Isselbacher EM *et al.* The international registry of acute aortic dissection (IRAD): new insights into an old disease. *JAMA* 2000; 283: 897–903.
- [116] Slater EE. Aortic Dissection: Presentation and diagnosis. In: Doroghazi RM, Slater EE, eds. *Aortic Dissection*. New York: McGraw-Hill, 1983: 61–70.
- [117] Fann JI, Sarris GE, Mitchell RS *et al.* Treatment of patients with aortic dissection presenting with peripheral vascular complications. *Ann Surg* 1990; 212: 705–13.
- [118] Roth JA, Parekh MA. Dissecting aneurysms perforating the esophagus. *N Engl J Med* 1978; 299: 776.
- [119] Spitzer S, Blanco G, Adam A, Spyrou PG, Mason D. Superior vena cava obstruction and dissecting aortic aneurysm. *JAMA* 1975; 233: 164–5.
- [120] Buja LM, Ali N, Fletcher RD, Roberts WC. Stenosis of the right pulmonary artery: a complication of acute dissecting aneurysm of the ascending aorta. *Am Heart J* 1972; 83: 89–92.
- [121] Yamada E, Matsumura M, Kyo S, Omoto R. Usefulness of a prototype intravascular ultrasound imaging in evaluation of aortic dissection and comparison with angiographic study, transesophageal echocardiography, computed tomography, and magnetic resonance imaging. *Am J Cardiol* 1995; 75: 161–5.
- [122] Spittell PC, Spittell JA Jr, Joyce JW *et al.* Clinical features and differential diagnosis of aortic dissection: experience with 236 cases (1980 through 1990). *Mayo Clin Proc* 1993; 68: 642–51.
- [123] Kamp TJ, Goldschmidt-Clermont PJ, Brinker JA, Resar JR. Myocardial infarction, aortic dissection, and thrombolytic therapy. *Am Heart J* 1994; 128: 1234–7.
- [124] Hartnell GG, Wakeley CJ, Tottle A, Papouchado M, Wilde RP. Limitations of chest radiography in discriminating between aortic dissection and myocardial infarction: implications for thrombolysis. *J Thorac Imaging* 1993; 8: 152–5.
- [125] Suzuki T, Katoh H, Watanabe M *et al.* Novel biochemical diagnostic method for aortic dissection. Results of a prospective study using an immunoassay of smooth muscle myosin heavy chain. *Circulation* 1996; 93: 1244–9.
- [126] Sarasin FP, Louis-Simonet M, Gaspoz JM, Junod AF. Detecting acute thoracic aortic dissection in the emergency department: time constraints and choice of the optimal diagnostic test. *Ann Emerg Med* 1996; 28: 278–88.
- [127] DeSanctis RW, Doroghazi RM, Austen WG, Buckley MJ. Aortic dissection. *N Engl J Med* 1987; 317: 1060–7.
- [128] Banning AP, Masani ND, Ikram S, Fraser AG, Hall RJ. Transesophageal echocardiography as the sole diagnostic investigation in patients with suspected thoracic aortic dissection. *Br Heart J* 1994; 72: 461–5.
- [129] Isselbacher EM, Cigarroa JE, Eagle KA. Cardiac tamponade complicating proximal aortic dissection. Is pericardiocentesis harmful? *Circulation* 1994; 90: 2375–8.
- [130] Eagle KA. Current management of aortic dissection — data from the International Registry for Aortic Dissection (IRAD). *Eur Soc Cardiol* 1999; 3278.
- [131] Bolognesi R, Manca C, Tsiatas D *et al.* Aortic intramural hematoma: an increasingly recognized aortic disease. *Cardiology* 1998; 89: 178–83.
- [132] Moriyama Y, Shiota K, Hisatomi K *et al.* Acute type A aortic dissection following intramural hematoma of the aorta. A case report. *Angiology* 1997; 48: 839–41.
- [133] Kang DH, Song JK, Song MG *et al.* Clinical and echocardiographic outcomes of aortic intramural haemorrhage compared with acute aortic dissection. *Am J Cardiol* 1998; 81: 202–6.
- [134] Flachskampf FA, Banbury M, Smedira N, Thomas JD, Garcia M. Transesophageal echocardiography diagnosis of intramural hematoma of the ascending aorta: a word of caution. *J Am Soc Echocardiogr* 1999; 12: 866–70.
- [135] Baur A, Stabler A, Bittmann I, Marmarakis G, Reiser M. [Penetrating aortic ulceration: an unusual form of aortic dissection]. *Fortschr Rontgenstr* 1998; 168: 550–6.



- [136] Just M, Mohr-Kahaly S, Kreitner KF *et al.* [Magnetic resonance tomography of chronic aortic dissection]. *Fortschr Rontgenstr* 1993; 158: 109–14.
- [137] Sommer T, Fehske W, Holzknicht N *et al.* Aortic dissection: a comparative study of diagnosis with spiral CT, multiplanar transesophageal echocardiography, and MR imaging. *Radiology* 1996; 199: 347–52.
- [138] Nienaber CA, von Kodolitsch Y. [Diagnostic imaging of aortic diseases]. *Radiologe* 1997; 37: 402–9.
- [139] von Segesser LK, Genoni M, Kunzli A *et al.* Surgery for ruptured thoracic and thoraco-abdominal aortic aneurysms. *Eur J Cardiothorac Surg* 1996; 10: 996–1001; discussion 1002.
- [140] Murgo S, Dussaussois L, Golzarian J *et al.* Penetrating atherosclerotic ulcer of the descending thoracic aorta: treatment by endovascular stent-graft. *Cardiovasc Intervent Radiol* 1998; 21: 454–8.
- [141] Eggebrecht H, Baumgart D, Herold U, Jakob H, Erbel R. Multiple penetrating atherosclerotic ulcers of the abdominal aorta: treatment by endovascular stent-graft placement. *Heart* 2001; 85: 526.
- [142] Kaji S, Nishigami K, Akasaka T *et al.* Prediction of progression or regression of type A aortic intramural haematoma by computed tomography. *Circulation* 1999; 100: II-281–6.
- [143] Zotz R, Stern H, Mohr-Kahaly S *et al.* [Coronary insufficiency in type II aortic dissection]. *Z Kardiol* 1987; 76: 784–6.
- [144] Kern MJ, Serota H, Callicot P *et al.* Use of coronary arteriography in the preoperative management of patients undergoing urgent repair of the thoracic aorta. *Am Heart J* 1990; 119: 143–8.
- [145] Creswell LL, Kouchoukos NT, Cox JL, Rosenbloom M. Coronary artery disease in patients with type A aortic dissection. *Ann Thorac Surg* 1995; 59: 585–90.
- [146] Pereira L, Levran O, Ramirez F *et al.* A molecular approach to the stratification of cardiovascular risk in families with Marfan's syndrome. *N Engl J Med* 1994; 331: 148–53.
- [147] Lee B, Godfrey M, Vitale E *et al.* Linkage of Marfan syndrome and a phenotypically related disorder to two different fibrillin genes. *Nature* 1991; 352: 330–4.
- [148] Godfrey M, Vandemark N, Wang M *et al.* Prenatal diagnosis and a donor splice site mutation in fibrillin in a family with Marfan syndrome. *Am J Hum Genet* 1993; 53: 472–80.
- [149] Rantamaki T, Raghunath M, Karttunen L, Lonnqvist L, Child A, Peltonen L. Prenatal diagnosis of Marfan syndrome: identification of a fibrillin-1 mutation in chorionic villus sample. *Prenat Diagn* 1995; 15: 1176–81.
- [150] Sermon K, Lissens W, Messiaen L *et al.* Preimplantation genetic diagnosis of Marfan syndrome with the use of fluorescent polymerase chain reaction and the Automated Laser Fluorescence DNA Sequencer. *Fertil Steril* 1999; 71: 163–6.
- [151] Mintz GS, Kotler MN, Segal BL, Parry WR. Two-dimensional echocardiographic recognition of the descending thoracic aorta. *Am J Cardiol* 1979; 44: 232–8.
- [152] Khandheria BK, Tajik AJ, Taylor CL *et al.* Aortic dissection: review of value and limitations of two-dimensional echocardiography in a six-year experience. *J Am Soc Echocardiogr* 1989; 2: 17–24.
- [153] Keren A, Kim CB, Hu BS, Eynogorina I *et al.* Accuracy of biplane and multiplane transesophageal echocardiography in diagnosis of typical acute aortic dissection and intramural hematoma. *J Am Coll Cardiol* 1996; 28: 627–36.
- [154] Buck TH, Gorge G, Hunold P, Erbel R. Three-dimensional imaging in aortic disease by lighthouse transesophageal echocardiography using intravascular ultrasound catheters. *J Am Soc Echocardiogr* 1998; 11: 243–58.
- [155] Erbel R, Mohr-Kahaly S, Oelert H *et al.* Diagnostic strategies in suspected aortic dissection: comparison of computed tomography, aortography and transesophageal echocardiography. *Am J Card Imaging* 1990; 4: 157–72.
- [156] Perry GJ, Helmcke F, Nanda NC, Byard C, Soto B. Evaluation of aortic insufficiency by Doppler color flow mapping. *J Am Coll Cardiol* 1987; 9: 952–9.
- [157] Iliceto S, Ettore G, Francisco G, Antonelli G, Biasco G, Rizzon P. Diagnosis of aneurysm of the thoracic aorta. Comparison between two non invasive techniques: two-dimensional echocardiography and computed tomography. *Eur Heart J* 1984; 5: 545–55.
- [158] Guéret P, Sénéchal C, Roudaut R. Comparison of transesophageal and transthoracic echocardiography in acute aortic dissection. A multicenter prospective study. *J Am Coll Cardiol* 1991; 17: 264.
- [159] Nienaber CA, Spielmann RP, von Kodolitsch Y *et al.* Diagnosis of thoracic aortic dissection. Magnetic resonance imaging versus transesophageal echocardiography. *Circulation* 1992; 85: 434–47.
- [160] Nienaber CA, von Kodolitsch Y, Nicolas V *et al.* The diagnosis of thoracic aortic dissection by noninvasive imaging procedures. *N Engl J Med* 1993; 328: 1–9.
- [161] Kersting-Sommerhoff BA, Higgins CB, White RD, Sommerhoff CP, Lipton MJ. Aortic dissection: Sensitivity and specificity of MR imaging. *Radiology* 1988; 166: 651–5.
- [162] Yang PC, Kerr AB, Liu AC *et al.* New real-time interactive cardiac magnetic resonance imaging system complements echocardiography. *J Am Coll Cardiol* 1998; 32: 2049–56.
- [163] Prince MR, Narasimham DL, Jacoby WT *et al.* Three-dimensional gadolinium-enhanced MR angiography of the thoracic aorta. *Am J Roentgenol* 1996; 166: 1387–97.
- [164] Krinsky GA, Rofsky NM, DeCorato DR *et al.* Thoracic aorta: comparison of gadolinium-enhanced three-dimensional MR angiography with conventional MR imaging. *Radiology* 1997; 202: 183–93.
- [165] Deutsch HJ, Sechtem U, Meyer H, Theissen P, Schicha H, Erdmann E. Chronic aortic dissection: comparison of MR imaging and transesophageal echocardiography. *Radiology* 1994; 192: 645–50.
- [166] Wagner S, Auffermann W, Buser P *et al.* Diagnostic accuracy and estimation of the severity of valvular regurgitation from the signal void on cine magnetic resonance images. *Am Heart J* 1989; 118: 760–7.
- [167] Pelc NJ, Herfkens RJ, Shimakawa A, Enzmann DR. Phase contrast cine magnetic resonance imaging. *Magn Reson Q* 1991; 7: 229–54.
- [168] Honda T, Hamada M, Matsumoto Y, Matsouka H, Hiwada K. Diagnosis of Thrombus and Blood Flow in Aortic Aneurysm using Tagging Cine Magnetic Resonance Imaging. *Int J Angiol* 1999; 8: 57–61.
- [169] van Rossum AC, Post JC, Visser CA. Coronary imaging using MRI. *Herz* 1996; 21: 97–105.
- [170] Solomon SL, Brown JJ, Glazer HS, Mirowitz SA, Lee JK. Thoracic aortic dissection: pitfalls and artifacts in MR imaging. *Radiology* 1990; 177: 223–8.
- [171] Wolff KA, Herold CJ, Tempany CM, Parravano JG, Zerhouni EA. Aortic dissection: atypical patterns seen at MR imaging. *Radiology* 1991; 181: 489–95.
- [172] Robb GP, Steinberg I. Visualization of chambers of heart, pulmonary circulation and great blood vessels in man: a practical method. *Am J Roentgenol* 1939; 41: 1–17.
- [173] Dinsmore RE, Rourke JA, DeSanctis RW, Harthorne JW, Austen WG. Angiographic findings in dissecting aortic aneurysm. *N Engl J Med* 1966; 275: 1152–7.
- [174] Shuford WH, Sybers RG, Weens HS. Problems in the aortographic diagnosis of dissecting aneurysms of the aorta. *N Engl J Med* 1969; 280: 225–31.
- [175] Sanders C. Current role of conventional and digital aortography in the diagnosis of aortic disease. *J Thorac Imaging* 1990; 5: 48–59.
- [176] Williams DM, Lee DY, Hamilton BH *et al.* The dissected aorta: part III. Anatomy and radiologic diagnosis of branch vessel compromise. *Radiology* 1997; 203: 37–44.
- [177] Rackson ME, Lossef SV, Sos TA. Renal artery stenosis in patients with aortic dissections: increasing prevalence. *Radiology* 1990; 177: 555–8.
- [178] Khandheria BK. Aortic dissection: the last frontier. *Circulation* 1993; 87: 1765–8.

- [179] Cigarroa JE, Isselbacher FM, De Sanctis RW, Eagle KA. Diagnostic imaging in the evaluation of suspected aortic dissection. Old standards and new directions. *N Engl J Med* 1993; 328: 35–43.
- [180] Chirillo F, Cavallini C, Longhini C *et al.* Comparative diagnostic value of transesophageal echocardiography and retrograde aortography in the evaluation of thoracic aortic dissection. *Am J Cardiol* 1994; 74: 590–5.
- [181] Eagle KA, Quertermous T, Kritzer GA *et al.* Spectrum of conditions initially suggesting acute aortic dissection but with negative aortograms. *Am J Cardiol* 1986; 57: 322–6.
- [182] Bansal RC, Chandrasekaran K, Ayala K, Smith DC. Frequency and explanation of false negative diagnosis of aortic dissection by aortography and transesophageal echocardiography. *J Am Coll Cardiol* 1995; 25: 1393–401.
- [183] Deeb GM, Williams DM, Bolling SF *et al.* Surgical delay for acute type A dissection with malperfusion. *Ann Thorac Surg* 1997; 64: 1669–75; discussion 1675–7.
- [184] Gorge G, Ge J, Haude M, Baumgart D, Buck T, Erbel R. Initial experience with a steerable intravascular ultrasound catheter in the aorta and pulmonary artery. *Am J Cardiac Imaging* 1995; 9: 180–4.
- [185] Bruce CJ, Packer DL, Seward JB. Transvascular Imaging: Feasibility Study Using a Vector Phase Array Ultrasound Catheter. *Echocardiography* 1999; 16: 425–30.
- [186] Borst HG, Lass J, Haverich A. A new look at acute type-A dissection of the aorta. *Eur J Cardiothorac Surg* 1987; 1: 186–9.
- [187] Lemole GM, Strong MD, Spagna PM, Karmilowicz NP. Improved results for dissecting aneurysms. Intraluminal sutureless prosthesis. *J Thorac Cardiovasc Surg* 1982; 83: 249–55.
- [188] Najafi H, Dye WS, Javid H, Hunter JA, Goldin MD, Julian OC. Acute aortic regurgitation secondary to aortic dissection. Surgical management without valve replacement. *Ann Thorac Surg* 1972; 14: 474–82.
- [189] Culliford AT, Ayvaliotis B, Shemin R, Colvin SB, Isom OW, Spencer FC. Aneurysms of the ascending aorta and transverse arch: surgical experience in 80 patients. *J Thorac Cardiovasc Surg* 1982; 82: 701–10.
- [190] Miller DC. Surgical management of acute aortic dissection: new data. *Semin Thorac Cardiovasc Surg* 1991; 3: 225–37.
- [191] Fraser CD, Wang N, Mee RB *et al.* Repair of insufficient bicuspid aortic valves. *Ann Thorac Surg* 1994; 58: 386–90.
- [192] Gott VL, Cameron DE, Pyeritz RE *et al.* Composite graft repair of Marfan aneurysm of the ascending aorta: results in 150 patients. *J Card Surg* 1994; 9: 482–9.
- [193] Kouchoukos NT, Wareing TH, Murphy SF, Perrillo JB. Sixteen-year experience with aortic root replacement. Results in 172 operations. *Ann Surg* 1991; 214: 308–18; discussion 318–20.
- [194] Bentall H, De Bono A. A technique for complete replacement of the ascending aorta. *Thorax* 1968; 23: 338–9.
- [195] Kouchoukos NT, Karp RB, Blackstone EH, Kirklin JW, Pacifico AD, Zorn GL. Replacement of the ascending aorta and aortic valve with a composite graft. Results in 86 patients. *Ann Surg* 1980; 192: 403–13.
- [196] David TE, Feindel CM. An aortic valve-sparing operation for patients with aortic incompetence and aneurysm of the ascending aorta. *J Thorac Cardiovasc Surg* 1992; 103: 617–21; discussion 622.
- [197] Sarsam MA, Yacoub M. Remodeling of the aortic valve annulus. *J Thorac Cardiovasc Surg* 1993; 105: 435–8.
- [198] Bachet J, Gigou F, Laurian C, Bical O, Goudot B, Guilmet D. Four-year clinical experience with the gelatin-resorcine-formol biological glue in acute aortic dissection. *J Thorac Cardiovasc* 1982; 83: 212–7.
- [199] Pego-Fernandes PM, Stolf NA, Moreira LF, Pereira Barreto AC, Bittencourt D, Jatene AD. Management of aortic insufficiency in chronic aortic dissection. *Ann Thorac Surg* 1991; 51: 438–42.
- [200] Frater RW. Aortic valve insufficiency due to aortic dilatation: correction by sinus rim adjustment. *Circulation* 1986; 74 I: 136–42.
- [201] Ergin MA, O'Connor J, Guinto R, Griep RB. Experience with profound hypothermia and circulatory arrest in the treatment of aneurysms of the aortic arch. Aortic arch replacement for acute aortic arch dissections. *J Thorac Cardiovasc Surg* 1982; 84: 649–55.
- [202] Heinemann M, Laas J, Jurmann M, Karck M, Borst HG. Surgery extended into the aortic arch in acute type A dissection. Indications, techniques and results. *Circulation* 1991; 84: III25–30.
- [203] Bachet J, Guilmet D, Goudot B *et al.* Cold cerebroplegia. *J Thorac Cardiovasc Surg* 1991; 102: 85–93; discussion 93–4.
- [204] Griep RB, Ergin MA, Lansman SL, Galla JD, Pogo G. The physiology of hypothermic circulatory arrest. *Semin Thorac Cardiovasc Surg* 1991; 3: 188–93.
- [205] Borst HG, Walterbusch G, Schaps D. Extensive aortic replacement using 'elephant trunk' prosthesis. *Thorac Cardiovasc Surg* 1983; 31: 37–40.
- [206] Borst HG, Frank G, Schaps D. Treatment of extensive aortic aneurysms by a new multiple-stage approach. *J Thorac Cardiovasc Surg* 1988; 95: 11–3.
- [207] Yoshinaga M, Oku S, Nomura Y, Nagai E. A case of Marfan syndrome in an adolescent with aortic dissection: should the recommendation for surgical intervention be changed? *Pediatr Cardiol* 1999; 20: 431–4.
- [208] Treasure T. Elective replacement of the aortic root in Marfan's syndrome. *Br Heart J* 1993; 69: 101–3.
- [209] Walker PJ, Miller DC. Aneurysmal and ischaemic complications of type B (type III) aortic dissections. *Semin Vasc Surg* 1992; 5: 198–214.
- [210] Cambria RP, Brewster DC, Gertler J *et al.* Vascular complications associated with spontaneous aortic dissection. *J Vasc Surg* 1988; 7: 199–209.
- [211] Elefteriades JA, Hammond GL, Gusberg RJ, Kopf GS, Baldwin JC. Fenestration revisited: a safe and effective procedure for descending aortic dissection. *Arch Surg* 1990; 125: 786–90.
- [212] Laas J, Heinemann M, Schaeffers HJ, Daniel W, Borst HG. Management of thoracoabdominal malperfusion in aortic dissection. *Circulation* 1991; 84: III20–4.
- [213] Elefteriades JA, Hartleroad J, Gusberg RJ *et al.* Long-term experience with descending aortic dissection: the complication-specific approach. *Ann Thorac Surg* 1992; 53: 11–20; discussion 20–1.
- [214] Fann JJ, Sarris GE, Sarris GE, Mitchell RS *et al.* Treatment of patients with aortic dissection presenting with peripheral vascular complications. *Ann Surg* 1990; 212: 705–13.
- [215] Miller DC, Mitchell RS, Oyer PE, Stinson EB, Jamieson SW, Shumway NE. Independent determinants of operative mortality for patients with aortic dissections. *Circulation* 1984; 70: 153–64.
- [216] Williams DM, Brothers TE, Messina LM. Relief of mesenteric ischaemia in type III aortic dissection with percutaneous fenestration of the aortic septum. *Radiology* 1990; 174: 450–2.
- [217] Cowling MG, Redwood D, Buckenham TM. Case report: critical lower limb ischaemia due to aortic dissection relieved by percutaneous transfemoral fenestration. *Clin Radiol* 1995; 50: 654–7.
- [218] Faykus MH Jr, Hiette P, Koopot R. Percutaneous fenestration of a type I aortic dissection for relief of lower extremity ischaemia. *Cardiovasc Intervent Radiol* 1992; 15: 183–5.
- [219] Gorge G, Erbel R. [Intravascular ultrasound for monitoring percutaneous fenestration of a membrane from an aortic dissection]. *Dtsch Med Wochenschr* 1996; 121: 1598–602.
- [220] Trerotola SO. Use of a stone basket as a target during fenestration of aortic dissection. *J Vasc Interv Radiol* 1996; 7: 687–90.
- [221] Kato N, Sakuma H, Takeda K, Hirano T, Nakagawa T. Relief of acute lower limb ischaemia with percutaneous

- fenestration of intimal flap in a patient with type III aortic dissection — a case report. *Angiology* 1993; 44: 755–9.
- [222] Saito S, Arai H, Kim K, Aoki N, Tsurugida M. Percutaneous fenestration of dissecting intima with a transseptal needle. *Cathet Cardiovasc Diagn* 1992; 26: 130–5.
- [223] Walker PJ, Dake MD, Mitchell RS, Miller DC. The use of endovascular techniques for the treatment of complications of aortic dissection. *J Vasc Surg* 1993; 18: 1042–51.
- [224] Williams DM, Lee DY, Hamilton BH, Marx MV, Narasimham DL, Kazanjian SN, Prince MR, Andrews JC, Cho KJ, Deeb GM. The dissected aorta: percutaneous treatment of ischaemic complications — principles and results. *J Vasc Interv Radiol* 1997; 8: 605–65.
- [225] Dake MD, Miller DC, Semba CP, Mitchell RS, Walker PJ, Liddell RP. Transluminal placement of endovascular stent-grafts for the treatment of descending thoracic aortic aneurysms. *N Engl J Med* 1994; 331: 1729–34.
- [226] Slonim SM, Nyman UR, Semba CP, Miller DC, Mitchell RS, Dake MD. True lumen obliteration in complicated aortic dissection: endovascular treatment. *Radiology* 1996; 201: 161–6.
- [227] Dake MD, Miller DC, Mitchell RS, Semba CP, Moore KA, Sakai T. The ‘first generation’ of endovascular stent-grafts for patients with aneurysms of the descending thoracic aorta. *J Thorac Cardiovasc Surg* 1998; 116: 689–703; discussion 703–4.
- [228] Nienaber CA, Fattori R, Lund G *et al.* Nonsurgical reconstruction of thoracic aortic dissection by stent-graft placement. *N Engl J Med* 1999; 340: 1539–45.
- [229] Borst HG, Jurmann M, Buhner B, Laas J. Risk of replacement of descending aorta with a standardized left heart bypass technique. *J Thorac Cardiovasc Surg* 1994; 107: 126–32; discussion 132–3.
- [230] de Baakey ME, McCollum CH, Graham JM. Surgical treatment of aneurysms of the descending aorta. *J Cardiovasc Surg* 1978; 19: 571–6.
- [231] Galloway AC, Schwartz DS, Culliford AT *et al.* Selective approach to descending thoracic aortic aneurysm repair: a ten-year experience. *Ann Thorac Surg* 1996; 62: 1152–7.
- [232] Inoue K, Sato M, Iwase T *et al.* Clinical endovascular placement of branched graft for type B aortic dissection. *J Thorac Cardiovasc Surg* 1996; 112: 1111–3.
- [233] Moon MR, Mitchell RS, Dake MD, Zarins CK, Fann JI, Miller DC. Simultaneous abdominal aortic replacement and thoracic stent-graft placement for multilevel aortic disease. *J Vasc Surg* 1997; 25: 332–40.
- [234] Lee DY, Williams DM, Abrams GD. The dissected aorta. part II. Differentiation of the true from the false lumen with intravascular US. *Radiology* 1997; 203: 32–6.
- [235] Shennan T. Dissecting aneurysm. Medical Research Council Special Report Series, No 193. London: Her Majesty’s Stationery Office, 1984.
- [236] Slonim SM, Nyman U, Semba CP, Miller DC, Mitchell RS, Dake MD. Aortic dissection: percutaneous management of ischaemic complications with endovascular stents and balloon fenestration. *J Vasc Surg* 1996; 23: 241–51; discussion 251–3.
- [237] Murray JW, Mann JJ, Genecin A, McKusick VA. Fever with dissecting aneurysm of the aorta. *Am J Med* 1976; 61: 140–4.
- [238] Link J, Muller-Hulsbeck S, Brossmann J, Steffens JC, Heller M. Perivascular inflammatory reaction after percutaneous placement of covered stents. *Cardiovasc Intervent Radiol* 1996; 19: 345–7.
- [239] Deeb GM, Williams DM, Bolling SF *et al.* Surgical delay for acute type A dissection with malperfusion. *Ann Thorac Surg* 1997; 64: 1669–75; discussion 1675–7.
- [240] Anagnostopoulos CE. Acute aortic dissection. Baltimore: University Park Press, 1975.
- [241] Asfoura JY, Vidt DG. Acute aortic dissection. *Chest* 1991; 99: 724–9.
- [242] Fuster V, Halperin JL. Aortic dissection: a medical perspective. *J Card Surg* 1994; 9: 713–28.
- [243] Bickerstaff LK, Pairolero PC, Hollier LM *et al.* Thoracic aortic aneurysms: a population based study. *Surgery* 1982; 92: 1103–8.
- [244] Fowkes FG, Macintyre CC, Ruckley CV. Increasing incidence of aortic aneurysms in England and Wales. *Br Med J* 1989; 298: 33–5.
- [245] Meszaros I, Morocz J, Szlavi J *et al.* Epidemiology and clinicopathology of aortic dissection. *Chest* 2000; 117: 1271–8.
- [246] Glower DD, Speier RH, White WD, Smith LR, Rankin JS, Wolfe WG. Management and longterm outcome of aortic dissection. *Ann Surg* 1991; 214: 31–41.
- [247] Masuda Y, Takanashi K, Takasu J, Watanabe S. [Natural history and prognosis of medical treatment for the patients with aortic dissections]. *Nippon Geka Gakkai Zasshi* 1996; 97: 890–3.
- [248] Eagle KA, Bruckmann D, Isselbacher E *et al.* Predictive of mortality in patients with type A acute aortic dissections — results from the International Registry of Acute Aortic Dissection (IRAD). *J Am Coll Cardiol* 2000; 35: 323.
- [249] Wigle RL, Moran JM. Spontaneous healing of a traumatic thoracic aortic tear: case report. *J Trauma* 1991; 31: 280–3.
- [250] Di Cesare E, Di Renzi P, Pavone P, Marsili L, Castallo F, Passariello R. Postsurgical follow-up of aortic dissections by MRI. *Eur J Radiol* 1991; 13: 27–30.
- [251] Hara K, Yamaguchi T, Wanibuchi Y, Kurokawa K. The role of medical treatment of distal type aortic dissection. *Int J Cardiol* 1991; 32: 231–40.
- [252] Barron DJ, Livesey SA, Brown IW, Delaney DJ, Lamb RK, Monro JL. Twenty-year follow-up of acute type A dissection: the incidence and extent of distal aortic disease using magnetic resonance imaging. *J Card Surg* 1997; 12: 147–59.
- [253] Masani ND, Banning AP, Jones RA, Ruttley MS, Fraser AG. Follow-up of chronic thoracic aortic dissection: comparison of transesophageal echocardiography and magnetic resonance imaging. *Am Heart J* 1996; 131: 1156–63.
- [254] Maffei S, Baroni M, Terrazzi M *et al.* Ambulatory follow-up of aortic dissection: comparison between computed tomography and biplane transesophageal echocardiography. *Int J Card Imaging* 1996; 12: 105–11.
- [255] Bogaert J, Meyns B, Rademakers FE *et al.* Follow-up of aortic dissection: contribution of MR angiography for evaluation of the abdominal aorta and its branches. *Eur Radiol* 1997; 7: 695–702.
- [256] Ide K, Uchida H, Otsuji H *et al.* Acute aortic dissection with intramural hematoma: possibility of transition to classic dissection or aneurysm. *J Thorac Imaging* 1996; 11: 46–52.
- [257] Muluk SC, Kaufman JA, Torchiana DF, Gertler JP, Cambria RP. Diagnosis and treatment of thoracic aortic intramural hematoma. *J Vasc Surg* 1996; 24: 1022–9.
- [258] Murray JG, Manisali M, Flamm SD *et al.* Intramural hematoma of the thoracic aorta: MR image findings and their prognostic implications. *Radiol* 1997; 204: 349–55.
- [259] Pepi M, Campodonico J, Galli C *et al.* Rapid diagnosis and management of thoracic aortic dissection and intamural haematoma: a prospective study of advantages of multiplane vs. biplane transesophageal echocardiography. *Eur J Echocardiography* 2000; 1: 72–9.
- [260] Bolognesi R, Manca C, Tsialtas D *et al.* Aortic intramural hematoma: an increasingly recognized aortic disease. *Cardiology* 1998; 89: 178–83.
- [261] Kang DH, Song JK, Song MG *et al.* Clinical and echocardiographic outcomes of aortic intramural haemorrhage compared with acute aortic dissection. *Am J Cardiol* 1998; 81: 202–6.
- [262] Lenferink S, Sechtem U. [Diagnosis and therapy of an intramural hematoma of the ascending aorta]. *Dtsch Med Wschr* 2000; 125: 489–92.
- [263] Kaji S, Nishigami K, Akasaka T *et al.* Prediction of progression or regression of type A aortic intramural haematoma by computed tomography. *Circulation* 1999; 100: II281–6.
- [264] Vilacosta I, San Roman JA, Ferreiros J, Aragoncillo P, Mendez R, Castillo JA, Rollan MJ, Batlle E, Peral V,



- Sanchez-Harguindey L. Natural history and serial morphology of aortic intramural haematoma: a novel variant of aortic dissection. *Am Heart J* 1997; 134: 495–507.
- [265] Coady MA, Rizzo JA, Elefteriades JA. Pathologic variants of thoracic aortic dissections. Penetrating atherosclerotic ulcers and intramural haematomas. *Cardiol Clin* 1999; 17: 637–57.
- [266] Vilacosta I, San Roman JA, Aragoncillo P *et al.* Penetrating atherosclerotic aortic ulcer: documentation by transesophageal echocardiography. *J Am Coll Cardiol* 1998; 32: 83–9.
- [267] Hussain S, Glover JL, Bree R, Bendick PJ. Penetrating atherosclerotic ulcers of the thoracic aorta. *J Vasc Surg* 1989; 9: 710–7.
- [268] Ayella RJ, Hankins JR, Turney SZ, Cowley RA. Ruptured thoracic aorta due to blunt trauma. *J Trauma* 1977; 17: 199–205.
- [269] Smith MD, Cassidy JM, Souther S *et al.* Transesophageal echocardiography in the diagnosis of traumatic rupture of the aorta. *N Engl J Med* 1995; 332: 356–62.
- [270] Vignon P, Gueret P, Vedrinne JM *et al.* Role of transesophageal echocardiography in the diagnosis and management of traumatic aortic disruption. *Circulation* 1995; 92: 2959–68.
- [271] Vignon P, Rambaud G, Francois B, Preux PM, Lang RM, Gastinne H. Quantification of traumatic hemomediastinum using transesophageal echocardiography. *Chest* 1998; 113: 1475–80.
- [272] Ura M, Sakata R, Nakayama Y, Goto T. Ultrasonographic demonstration of manipulation-related aortic injuries after cardiac surgery. *J Am Coll Cardiol* 2000; 35: 1303–10.
- [273] Groenink M, Rozendaal L, Naeff MS *et al.* Marfan syndrome in children and adolescents: predictive and prognostic value of aortic root growth for screening for aortic complications. *Heart* 1998; 80: 163–9.
- [274] Gott VL, Greene PS, Alejo DE *et al.* Replacement of the aortic root in patients with Marfan's syndrome. *N Engl J Med* 1999; 340: 1307–13.
- [275] Finkbohner R, Johnston D, Crawford ES, Coselli J, Milewicz DM. Marfan syndrome. Long-term survival and complications after aortic aneurysm repair. *Circulation* 1995; 91: 728–33.
- [276] Silverman DI, Burton KJ, Gray J *et al.* Life expectancy in the Marfan syndrome. *Am J Cardiol* 1995; 75: 157–60.
- [277] Crawford ES, Coselli JS. Marfan's syndrome: combined composite valve graft replacement of the aortic root and transaortic mitral valve replacement. *Ann Thorac Surg* 1988; 45: 296–302.
- [278] McDonald GR, Schaff HV, Pyeritz RE, McKusick VA, Gott VL. Surgical management of patients with the Marfan syndrome and dilatation of the ascending aorta. *J Thorac Cardiovasc Surg* 1981; 81: 180–6.
- [279] American Academy of pediatrics Committee on Genetics. Health supervision for children with Marfan syndrome. *Pediatrics* 1996; 98: 978–82.
- [280] Taylor JFN. Clinical pediatric cardiology. *Curr Opin Cardiol* 1993; 8: 108–13.
- [281] Braverman AC. Exercise and the Marfan syndrome. *Med Sci Sports Exerc* 1998; 30: 387–95.
- [282] Neufang KF, Theissen P, Deider S, Sechtem U. [Thoracic aorta dissection — the place of MRT and CT in the follow-up after prosthetic aortic replacement]. *Fortschr Rontgenstr* 1989; 151: 659–65.
- [283] Rizzo JA, Darr U, Fischer M *et al.* Multimodality serial follow-up of thoracic aortic aneurysms. *Int J Angiol* 1997; 6: 153–6.
- [284] Murphy DA, Craver JM, Jones EL, Bone DK, Guyton RA, Hatcher CR Jr. Recognition and management of ascending aortic dissection complicating cardiac surgical operations. *J Thorac Cardiovasc Surg* 1983; 85: 247–56.
- [285] Gott JP, Cohen CL, Jones EL. Management of ascending aortic dissections and aneurysms early and late following cardiac operations. *J Card Surg* 1990; 5: 2–13.
- [286] Suzuki S, Kondo H, Imoto K *et al.* [Type A acute aortic dissection: late reoperations for dilatation of the distal false lumen and aortic regurgitation]. *Kyobu Geka* 1998; 51: 656–60.
- [287] Le Heuzey JY, Guize L, Guerinon J, Forman J, Sellier P, Maurice P. [Dissection of the ascending aorta after aortic valve replacement]. *Arch Mal Coeur Vaiss* 1983; 76: 1349–56.
- [288] von Kodolitsch Y, Simic O, Schwartz A *et al.* Predictors of proximal aortic dissection at the time of aortic valve replacement. *Circulation* 1999; 100 II: 287–94.
- [289] Albat B, Thevenet A. Dissecting aneurysms of the ascending aorta occurring late after aortic valve replacement. *J Cardiovasc Surg* 1992; 33: 272–5.
- [290] Derkac W, Laks H, Cohn LH, Collins JJ Jr. Dissecting aneurysms after aortic valve replacement. *Arch Surg* 1974; 109: 388–90.
- [291] Ralph-Edwards A, David TE, Bos J. Infective endocarditis in patients who had replacement of the aortic root. *Ann Thorac Surg* 1994; 58: 429–32.
- [292] Soyer R, Bessou JP, Bouchart F *et al.* Surgical treatment of infected composite graft after replacement of ascending aorta. *Ann Thorac Surg* 1994; 58: 425–8.
- [293] Kirklin JW, Barrat-Boyes BG. In: *Cardiac Surgery*, 2nd edn. New York: Churchill Livingstone, 1993; 2: 523–4.
- [294] Karck M, Cremer J, Wawersik J, Haverich A. Reoperation for aneurysmal disease of the ascending aorta in patients with concomitant aortic valve incompetence. *J Thorac Cardiovasc Surg* 1996; 112: 1392–3.
- [295] Crawford ES, Crawford JL, Safi HJ, Coselli JS. Redo operations for recurrent aneurysmal disease of the ascending aorta and transverse aortic arch. *Ann Thorac Surg* 1985; 40: 439–55.